

# Stereotactic Radiosurgery

## Bloodless Brain Surgery

By Michael H. Brisman, M.D., F.A.C.S.

### BACKGROUND

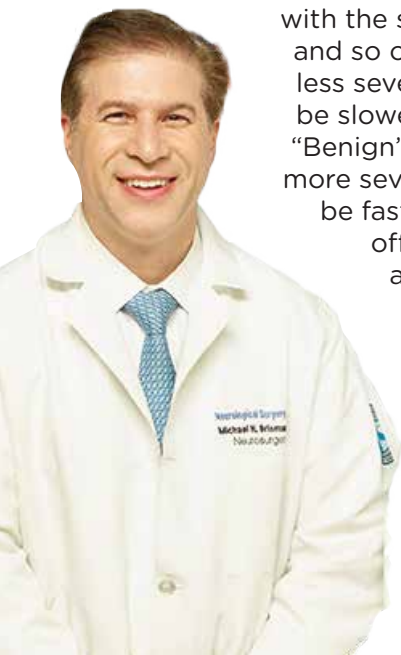#### What is Radiation?

Radiation is the emission of energy through space in the form of waves or particles. Radiation exists all around us. There are specific types of radiation that can be harmful or helpful to people, depending on the specific details.

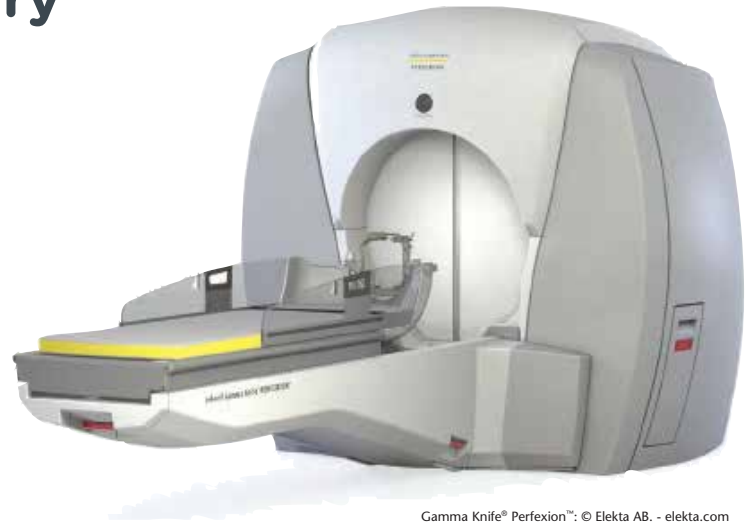#### What is a Tumor?

A tumor is an abnormal growth in the body. The body is made of many individual cells. Each cell has a nucleus filled with DNA that tells the cell what to do, including when to divide. If a problem occurs with the part of the DNA that controls cell growth that causes the cell to divide more frequently than normal, a tumor can develop. When the abnormal cell divides, there will then be two cells with the same cell growth defect, and so on. If the DNA problem is less severe, the growth tends to be slower and the tumor is called "Benign". If the DNA problem is more severe, the growth tends to be faster and the cells can break off from the primary tumor and spread ("metastasize") to another body part.

These tumors are called "Malignant" or "Cancers". Sometimes there are tumors of intermediate growth as well.



Michael H. Brisman, M.D., F.A.C.S.



Gamma Knife® Perfection™. © Elekta AB. - elekta.com

#### Does Radiation Cause Tumors or Treat Tumors?

Most tumors develop spontaneously. However, some tumors are caused by certain external factors. Factors that can induce cancer development are called "carcinogens". These agents can cause damage to the cell DNA, which can in turn cause a tumor to develop. For example, cigarette smoking can, over time, cause a lung cancer to develop. Similarly, excessive exposure to sunlight, a type of radiation, can, over time, cause a skin cancer to develop. Radiation, particularly certain types with certain intensities, can also cause other tumors or cancers to develop, because radiation can damage DNA.

Radiation can also be used as a treatment for tumors and other diseases. Radiation therapy uses radiation to induce damage to certain tumors and certain body tissues to treat medical problems. **Thus, radiation can shrink or stabilize the growth of tumors.** There is some risk, albeit low, that this radiation therapy can cause some harm to normal tissues.


## What is “Standard Radiation” Treatment?

Traditional Radiation Therapy, also known as External Beam Radiation Therapy (EBRT), usually involves aiming relatively wide field radiation beams at a cancerous target. The treatments are usually performed with Linear Accelerators (LINACS) that emit X-RAYS. A small amount of radiation is given each day for 10-30 days. Cells that are actively dividing, like cancer cells, are more susceptible to damage from this type of radiation treatment. Much normal tissue is exposed to this type of radiation, but because most normal cells are not dividing, they are not unduly affected by the treatment. There are, however, some normal cells that are normally dividing frequently (like hair cells) that can also be affected. For this reason, there can be temporary hair loss after standard radiation treatments.

A key point to radiation therapy is that it takes some time to work. For certain benign diseases, this can be months or years. Therefore, if urgent treatment or decompression is needed, surgery may first be necessary.

## What is “Stereotactic Radiosurgery” (SRS)?

The word “stereotactic” refers to a technique for accurate localization of a target in three dimensional space. The word “radiosurgery” refers to a technique of using highly focused radiation beams on a biological target so as to cause the same effect as one would expect with traditional open surgery. “Stereotactic Radiosurgery” or “SRS” is therefore a technique where highly accurate localizing technology is used to direct a highly focused radiation treatment at a target in the human brain, spine, or body. Sometimes Stereotactic Radiosurgery is just referred to as “Radiosurgery”.



Radiosurgery is one solution to the problem of how to use a minimally invasive technique to effectively treat deep structures without harming the more superficial structures that the treatment must pass through.

## Who Performs Radiation and Radiosurgery?

Standard Radiation Treatment is performed by a Radiation Oncologist. Most Radiosurgery involves treatments to the Brain, Spine, and Spinal Cord, and is performed by a Neurosurgeon who specializes in Radiosurgery, and a Radiation Oncologist. Body Radiosurgery, that is, Radiosurgery outside of the Brain, Spine, and Spinal Cord, is performed by a Radiation Oncologist, sometimes with the help of a surgeon who specializes in the body region being treated. A physicist is also involved in all Radiation treatments, both standard radiation and Radiosurgery.

## The Key Features of Radiosurgery

There are three key features of Radiosurgery, regardless of how the treatment is delivered.

1. The radiation treatment is **HIGHLY CONFORMAL** to the desired target
2. The radiation treatment has a very **RAPID FALL-OFF OF RADIATION DOSE** from the desired target
3. The radiation treatment is done in **ONE OR JUST A FEW SESSIONS**

Radiosurgery is a focused treatment technique. As such, it is appropriate for certain “focused” anatomic medical problems. Disease that is “diffuse” or lacks a well defined visual target, will usually not benefit.

## The Invention and History of Radiosurgery

Radiosurgery was invented in the 1950’s by the Swedish Neurosurgeon Lars Leksell. He created the first Radiosurgery machine called a “Gamma Knife”.

A major limitation at the time was the inability to get good images of disease targets. The only imaging that was available then was x-rays, and “angiography” (imaging of blood vessels by injecting material into them that could be seen on x-ray). For this reason, much of the early Radiosurgery treatments were directed at abnormalities of brain blood vessels called arteriovenous malformations (AVM’s), which could be seen on angiography (and thus could be targeted).

The proliferation of outstanding live imaging techniques (CAT scans in the 1970's and MRI's in the 1980's) allowed for the great expansion of Radiosurgery to many other uses.

## How is Radiosurgery Accomplished?

There are two techniques for accomplishing Radiosurgery: **Convergence of Radiation Beams** and **Charged Particle Beams**.

### 1. Convergence of Radiation Beams

By having hundreds of beams converge at the target, the target will receive an effective dose but the surrounding tissues will receive only one beam or a very tiny, insignificant dose. This is the method used for 99% of Radiosurgery treatments. There are two types of devices that use the Convergence of Beams technique.

#### a. Gamma Knife

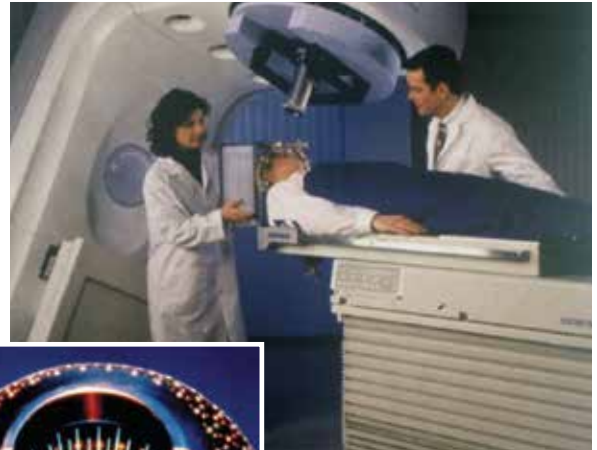The Gamma Knife uses GAMMA RAYS, a type of radiation, to focus on a target in the brain. Treatments usually involve a stereotactic headframe, treat only brain disease, and are performed in a single session.

#### b. Linear Accelerators (LINACS)

LINACS use XRAYs, another type of radiation, and are the machines that are used for traditional body radiation treatments. Specialized LINACS have been created that can perform Radiosurgery, and can focus on targets in the brain, the spine and the body. LINAC treatments are usually performed with a rigid face mask or body immobilizing device, and can be performed in 1-5 sessions. Examples of LINAC Radiosurgery systems include CYBERKNIFE and NOVALIS TX.

### 2. Charged Particle Beams

Very large machines called cyclotrons can emit radiation beams of charged particles, usually either PROTONS (hydrogen nuclei) or HELIUM IONS. The nature of these particle beams is that they emit most of their radiation at a known distance from the emission site, at what is called the "Bragg peak". Thus by positioning the target at this known location, the radiation energy is almost all deposited at



the desired target depth. Most charged particle treatments use PROTON BEAM machines, though again, this

represents less than 1% of all Radiosurgery treatments done. Cyclotron machines are extremely large and expensive and do not clearly provide better treatments compared with the more standard machines.

## Radiosurgery Delivery:

### Single Session Radiosurgery

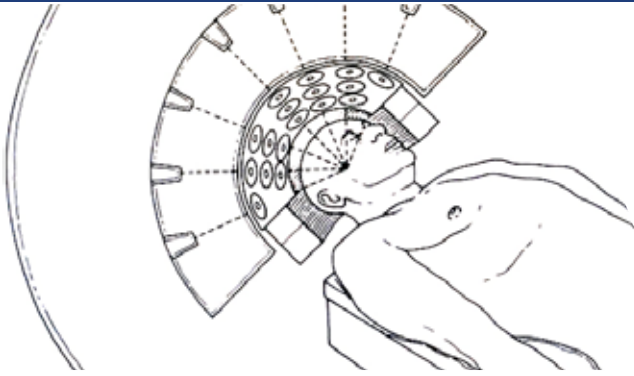
Radiosurgery was initially designed as a SINGLE SESSION TREATMENT, and this is still the most commonly used type of treatment.

### Hypofractionated Radiosurgery

In some cases, particularly if the target is larger than average or is near certain critical structures (like the optic nerves or the brainstem), Radiosurgery can be performed over a few sessions. Radiosurgery performed over 2-5 sessions is called HYPOFRACTIONATED RADIOSURGERY.

### Staged Radiosurgery

In some cases, particularly with very large targets, the Radiosurgery treatment may be STAGED, that is, part of the target is treated, and then, months later, the other parts of the target are treated.



### Repeat Radiosurgery

Sometimes there will be a need to repeat the Radiosurgery treatment to the same target. For example, a tumor that was treated with Radiosurgery may recur over time. In this case, the Radiosurgery treatment might be repeated on roughly the same target, usually over a year after the initial treatment.

### Multiple Target Radiosurgery

Sometimes there are multiple targets that will require Radiosurgery treatment. These may be recognized from the outset (for example, someone with three small metastatic brain tumors), and the Radiosurgery treatment could treat all targets in the initial session. It is also possible, that multiple targets are known from the outset, but a decision is made to treat one target initially, and then another at a later time. It is also possible, that at the time of the initial treatment, certain targets were known, and then, at some time in the future, another problem develops (such as a new metastatic tumor) that requires an additional Radiosurgery treatment.

## Comparing Stereotactic Radiosurgery (SRS) to Standard External Beam Radiation Therapy (EBRT)

Radiosurgery is different from standard radiation therapy in several important ways. Radiosurgery uses relatively higher doses of radiation in each session for 1-5 sessions to a very small field. Standard radiation uses relatively lower doses of radiation in each session for 10-30 sessions to a larger area or field. Radiosurgery uses a high enough very focused dose of radiation so that it can treat benign or malignant disease or even normal tissues in some circumstances. Standard radiation therapy treats malignant (cancerous) tumors, taking advantage of the DIFFERENTIAL SENSITIVITIES of the cancer cells

versus normal tissues, to that particular dose of radiation. Radiosurgery is usually performed by a surgeon and radiation oncologist and a physicist. Standard radiation therapy is performed by a radiation oncologist and physicist alone.

## Dose Tolerances of Different Structures and Complication Avoidance

Different body tissues have different tolerances for radiation. For example, the optic nerves, the brain stem and the spinal cord, are particularly sensitive to radiation. Complications may be more likely when the treatment is near these more sensitive structures. Treatment plans are therefore designed to minimize radiation dose to these sensitive structures.

Complications are also more likely with increased radiation dose and larger treatment targets. Therefore, larger targets may benefit from fractionated treatments, staged treatments, or lower doses of radiation.

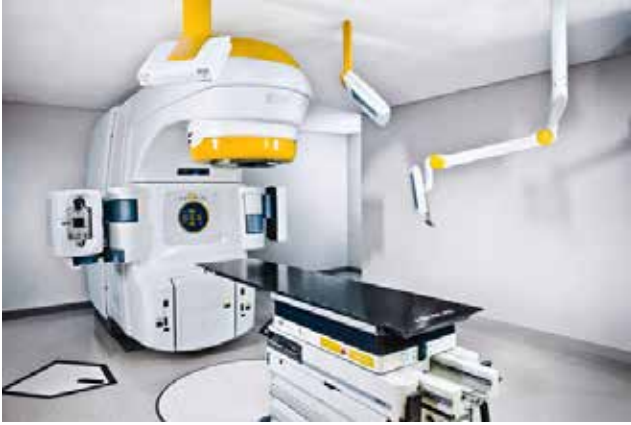One specific complication that can occur months to years after radiation or Radiosurgery is "RADIATION NECROSIS" or death of normal cells exposed to the radiation. This can lead to swelling at the affected area and clinical symptoms. Certain tests like an MRI or PET scan may help clarify if radiation necrosis has occurred. Radiation necrosis can be treated with steroids (like "Decadron"), or several weeks of special oxygen treatments called "hyperbaric oxygen", or sometimes, surgery.

If radiation causes general swelling in an area, the normal function of those tissues may be affected. Radiosurgery treatments to certain brain structures also carries a very small risk of seizure.

Radiation necrosis should be distinguished from the possibility of slight "normal" swelling that can occur to a tumor in the weeks or months following a radiosurgery treatment.







Novalis TX radiosurgery system

## The Timing of Radiosurgery

Once a decision has been made to perform Radiosurgery, the timing of actually performing the treatment depends on the disease being treated. In general, malignant or cancerous diseases can grow fairly quickly, so these are usually treated within 3-4 weeks. Benign diseases, on the other hand, can usually be treated more electively, within months.

# Brain Radiosurgery

Indications for Brain Radiosurgery can be divided into three general categories:

1. Brain Tumors
2. Brain Vascular Malformations
3. Brain Functional Disorders

## 1. Brain Tumors

Brain Tumors can further be subdivided into **Benign Brain Tumors** and **Malignant Brain Tumors**.

### Benign Brain Tumors

Brain Radiosurgery can be considered for any benign brain tumor. The most common types of benign brain tumors that are seen are **MENINGIOMAS**, **ACOUSTIC NEUROMAS**, and **PITUITARY TUMORS**.

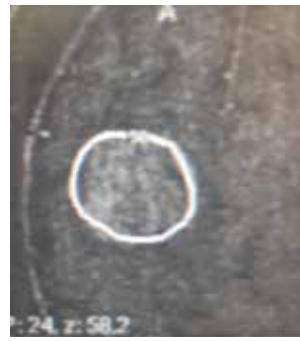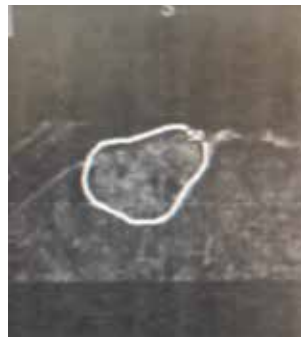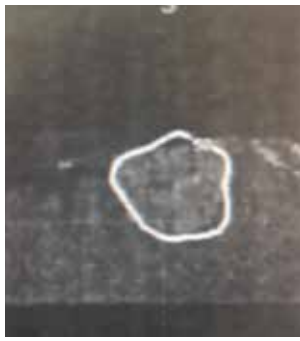### MENINGIOMAS

These are growths that are almost always benign, that arise from the covering layer of the brain, also known as the “meninges”. They can arise anywhere from this covering layer. They are classified on a 3 point World Health Organization (WHO) grading system. Grade 1 is benign, and is the most common type; Grade 2 is atypical, and is less common; Grade 3 is Malignant, and is rare. All types can potentially be treated with surgery and

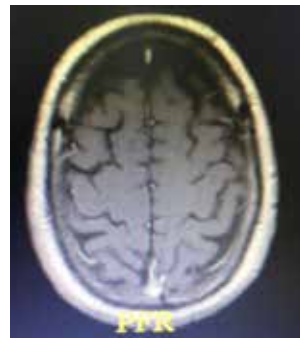
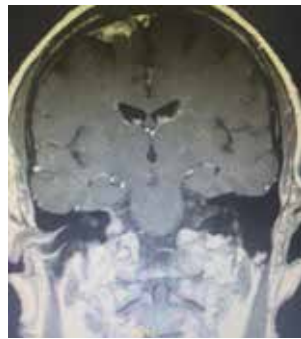
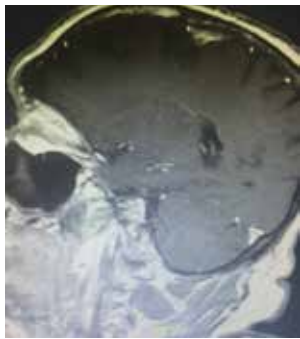
radiosurgery. Chemotherapy is usually reserved for malignant meningiomas, and sometimes atypical meningiomas.

Meningiomas that are very large will usually be surgically removed. Meningiomas that are very small or that show little change over time will frequently be observed with follow-up MRI imaging. Meningiomas of intermediate size, particularly if they are enlarging, are usually good candidates for Radiosurgery treatment. Meningiomas that are “residual” after surgery or “recur” after surgery would also be good candidates for Radiosurgery treatment.

Meningiomas that are large in which surgery might be higher risk may be considered for “staged” radiosurgery treatments. That is, part of the tumor might be treated in one Radiosurgery session, then, months later, the remaining tumor could be treated in a subsequent session.



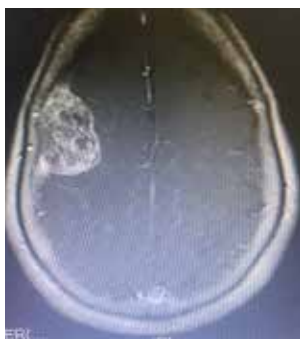At Treatment



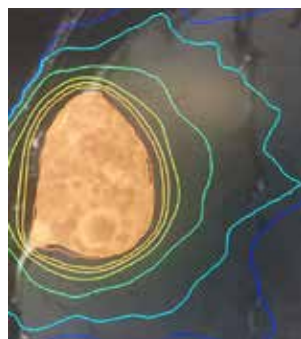
After Treatment

### Meningioma Case Study #1

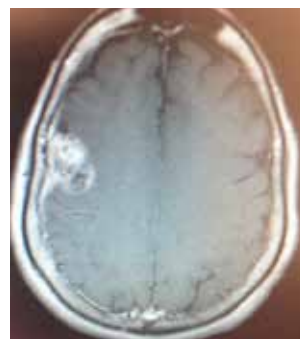
This is a 60 year old man found incidentally to have a right frontal/parietal meningioma. The tumor was noted to be enlarging over time. A Gamma Knife treatment was performed. 6 years later, the tumor had mostly disappeared. The patient remained neurologically intact.



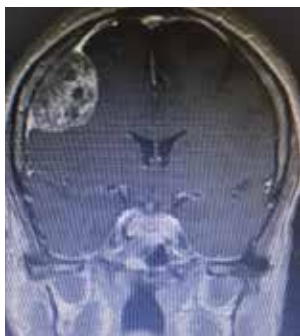Before Treatment



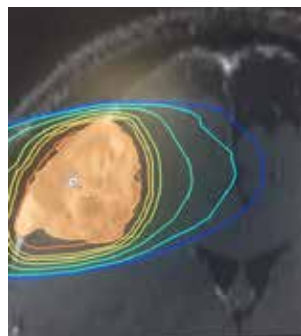
At Treatment



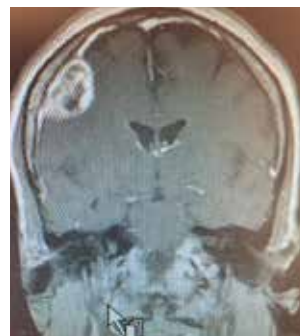
After Treatment



Before Treatment



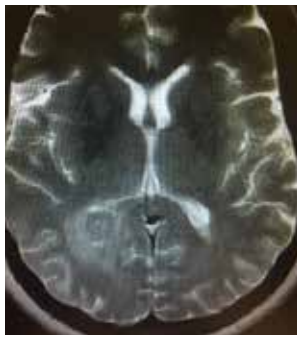At Treatment



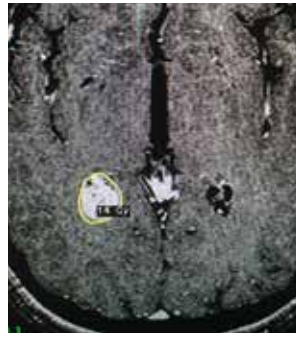
After Treatment

### Meningioma Case Study #2

This is a 67 year old physician who experienced some intermittent dizziness and was found to have a moderate sized right frontal meningioma. It was enlarging over time. She opted for a radiosurgery treatment. A Novalis Radiosurgery treatment was performed over 5 sessions. 3 years later, the tumor was much smaller, and the patient had no symptoms.



Before Treatment



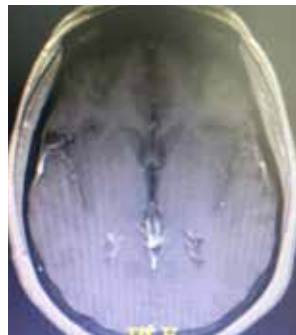
At Treatment



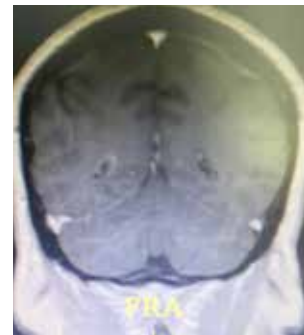
At Treatment

### Meningioma Case Study #3

This is a 52 year old woman who was found incidentally to have a right atrial meningioma with some surrounding edema. A Gamma knife treatment was performed. 3 years later, the patient is without symptoms and the MRI shows the tumor is gone.



After Treatment



After Treatment

## ACOUSTIC NEUROMAS

These are benign growths that arise from one of the two 8<sup>th</sup> cranial nerves (the right or the left), the nerves involved in hearing and balance. These tumors usually develop spontaneously, but can occur as a result of genetic factors. For example, there is a genetic disorder called **neurofibromatosis type 2 (NF2)**, in which people get acoustic neuromas on both the right and left 8<sup>th</sup> nerves. Acoustic neuromas can cause hearing loss and ringing in the ear, and dizziness and a sense of being off-balance. If they grow large enough, they can compress the brainstem and cause weakness of arms and legs, and other serious neurological problems.

Acoustic neuromas that are very small or that are stable over time can be watched. Tumors that are very large (over 3.5cm) are usually surgically removed or debulked. Most other acoustic neuromas are good candidates for Radiosurgery. Radiosurgery is about 95% effective. The remaining 5% of patients will ultimately need either a repeat Radiosurgery treatment or standard open surgery. Radiosurgery will preserve hearing at its current level about 60-70% of the time. Newer Radiosurgery techniques try to minimize the dose to the cochlea (one of the structures involved in hearing), and may improve hearing preservation. For almost all acoustic neuromas, Radiosurgery is as effective as surgery with a much lower risk profile.

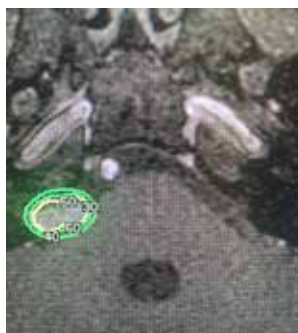


### Acoustic Neuroma Case Study #1

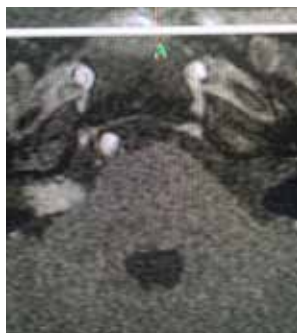This is a 58 year old woman found to have decreased hearing in the right ear (about 30% of normal). MRI showed a right acoustic neuroma. A Gamma Knife treatment was performed. 14 years later, the tumor remains stable and her hearing has been preserved at the pre-treatment level.



At Treatment



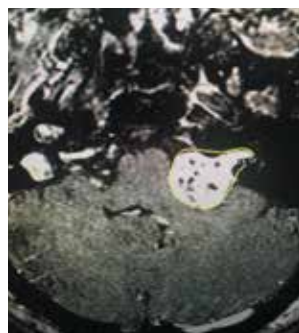
At Treatment



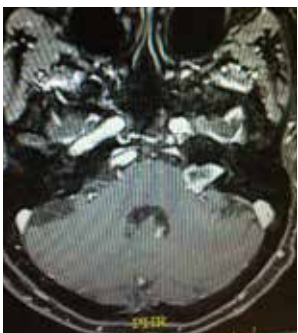After Treatment

### Acoustic Neuroma Case Study #2

This is a 66 year old woman who presented with decreased hearing in the left ear and was found to have a 2.3 cm left acoustic neuroma indenting the brainstem. She underwent gamma knife treatment. 6 years later, the tumor is much smaller. She still has hearing in the left ear, though it is less than it was when the tumor was first treated.



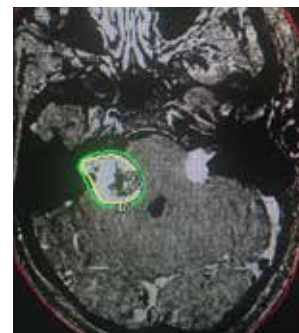
At Treatment



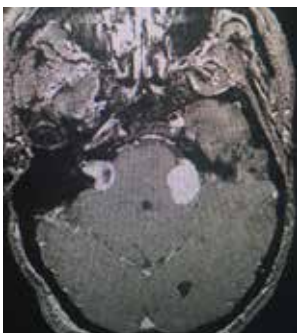
After Treatment

### Acoustic Neuroma Case Study #3

This is a 26 year old woman with neurofibromatosis type 2 who presented with significant decreased hearing in the right ear (about 10% of normal). MRI showed a large right acoustic neuroma with brainstem compression, and a much smaller left acoustic neuroma. Gamma Knife was performed on the right acoustic neuroma. 6 years later, the right acoustic neuroma was dramatically smaller, and the hearing in the right ear had improved significantly to about 80% of normal. The left acoustic neuroma subsequently was found to be enlarging and recently underwent Gamma Knife treatment as well.



At Treatment



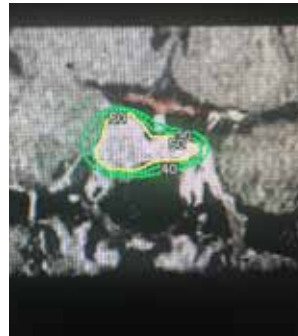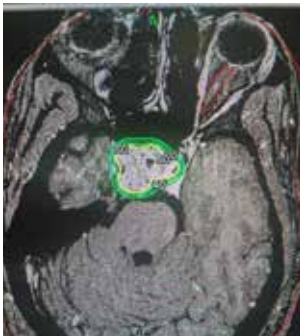
After Treatment



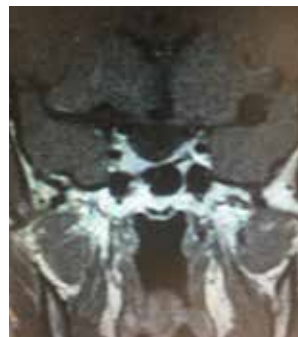
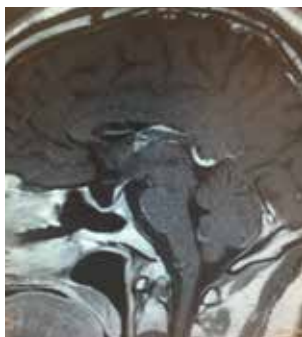
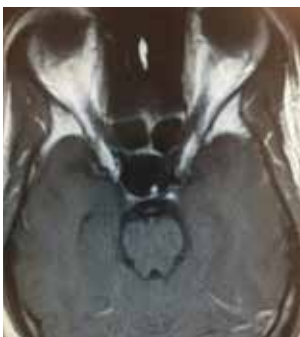## PITUITARY TUMORS

Pituitary adenomas are benign growths from cells of the pituitary gland. Tumors 1 cm or larger in size are called “macroadenomas” and tumors under 1cm in size are called “microadenomas”. These tumors may produce an excess of various pituitary hormones (“secretory” tumors) or may not produce any hormones (“non-secretory”). Pituitary tumors can also compress the normal pituitary gland and cause a deficiency of certain hormones. Pituitary tumors usually produce symptoms by either causing an excess or deficiency of pituitary hormones, or by compressing nerves that control the eye (affecting vision or eye movement). The most common type of secretory adenoma is a “**Prolactinoma**” and produces an excess of “prolactin” (a hormone involved in the production of breast milk). These tumors are usually treated with medicines alone. The other two major types of secretory pituitary tumors cause either “**Cushing’s Disease**” (in which people have too much steroid hormones in their bodies which can cause symptoms like diabetes, or hypertension, or a swollen face) or “**Acromegaly**” (in which people have too much growth hormone in their bodies and can get enlargement of their hands, feet, face, and internal organs).

Non-secretory microadenomas are usually treated with observation. Prolactinomas are usually treated with medication (such as “cabergoline”). Non-secretory macroadenomas, Cushing’s tumors and Acromegaly tumors are usually operated on transphenoidally (through the nostrils and the “sphenoid” sinus behind the nose), frequently with an endoscope, as are patients whose pituitary tumor presents with sudden swelling or bleeding (“pituitary apoplexy”). Radiosurgery is an excellent choice for residual or recurrent tumor after surgery, non-secretory adenomas that are not causing much compression of the optic chiasm, and for patients who would not otherwise be good candidates for surgery. Radiosurgery may cause some decrease in normal hormone production, which would then be treated with oral hormone supplements. Some patients with pituitary tumors will also need certain medicine treatments if their hormone levels remain too high (as in Cushing’s Disease or Acromegaly) or too low.



At Treatment



After Treatment

### Pituitary Tumor Case Study

This is a 45-year old man who, three years earlier, had undergone transsphenoidal removal of a non-secretory pituitary macroadenoma. The tumor had now recurred. Gamma Knife was performed. Six years later, the patient remained neurologically intact and the tumor had almost completely disappeared. The patient takes synthroid, but otherwise has normal endocrine function.

## BRAIN METASTASES

Brain Metastases are cancerous tumors that have spread to the brain from cancer in another body part. Brain Metastases are the most common type of symptomatic brain tumor in adults. The most common source of metastatic brain tumors are lung cancer, but other common types include breast cancer, renal cancer, melanoma (a type of skin cancer), and colon cancer.

Brain metastases are different in several ways from metastases to other body parts. First, they tend to produce significant amounts of swelling (edema) in the brain and frequently cause significant symptoms, out of proportion to their size. Second, they tend not to respond well to systemic chemotherapy — medicines used to treat malignant tumors — because the “blood-brain barrier” blocks many such chemicals from entering the brain.

Steroids (such as “Decadron”) can be used to temporarily reduce swelling around these tumors, and anticonvulsant medicines (such as “Keppra”) can be given if patients develop seizures. Radiosurgery has become the treatment of choice for most brain metastases, and this is currently the most common indication for Radiosurgery.

### Malignant Brain Tumors

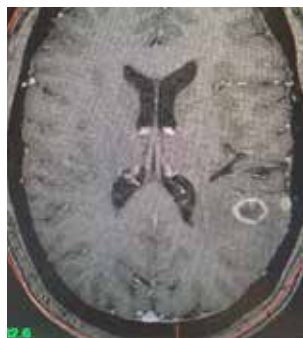Brain Radiosurgery can be considered for any malignant brain tumor. The most common types of malignant brain tumors are **METASTASES** and **ASTROCYTOMAS**.

Radiosurgery may be particularly favored over standard radiation for “**radioresistant tumors**” (tumors that don’t respond that well to traditional radiation treatments, like renal cancer, melanoma, and sarcoma). Traditional “whole brain radiation therapy” (WBRT) may be used when there are numerous brain metastases (for example, more than 10), or cases where some of the tumors are large. Surgery may be useful if there is a very large superficial metastasis that is causing symptoms.

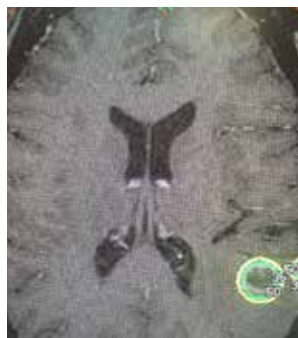Brain metastases are generally discrete processes. As such, Radiosurgery is often very effective at controlling these tumors. The issue is that these patients often have disease in the body which may be challenging to control.

### Brain Metastases Case Study

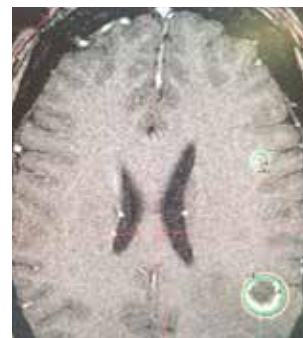
This is a 61 year old woman with non-small cell lung cancer found to have three brain metastases, one left frontal, and two left parietal. A Gamma Knife treatment was performed in which all three tumors were treated at the same time. Six years later, the tumors were all gone, and the patient remained neurologically intact.



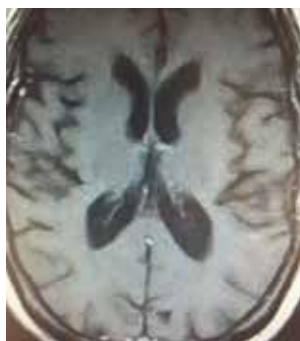
Before Treatment



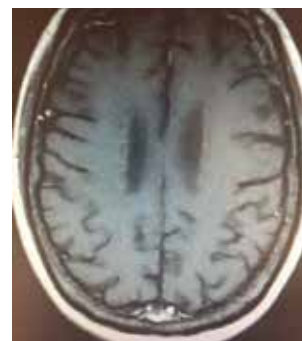At Treatment



At Treatment



After Treatment



After Treatment

## ASTROCYTOMA

The most common type of “primary” malignancy of the brain (cancer that originates in the brain) is the astrocytoma. Astrocytomas are tumors of the “supporting” cells in the brain (“astrocytes”). Astrocytomas are graded on a 4 point scale. Grade 1 are the rare benign childhood brain tumor called the “Juvenile Pilocytic Astrocytoma”. They are discrete and benign tumors that can be cured with surgical removal. Grade 2 are intermediate grade tumors that are usually seen in younger adults and people of middle age, and can gradually grow or turn into higher grade tumors. Grade 3 and 4 are high grade malignant tumors, Grade 3 being called Anaplastic Astrocytoma and Grade 4 being called Glioblastoma Multiforme. Malignant Astrocytomas (Grades 3 and 4) usually occur in middle aged people or the elderly.

Surgery is usually the first line of treatment for Astrocytomas. Wide field radiation is usually given for the high grade tumors, and can be considered for the Grade 2 tumors as well. Chemotherapy (such as “Temodar”) is also given for the high grade tumors, and sometimes for the grade 2 tumors. Radiosurgery can be considered for small to moderate sized Grade 1 and 2 tumors not amenable to surgery, and for recurrent high grade tumors of small to moderate size.

Astrocytomas Grades 2-4 are diffuse processes. As such, they are challenging to treat. Radiosurgery can treat some of the tumor, but these tumors are often fairly widespread. As such, they are not usually very susceptible to a “focused” treatment like radiosurgery, and lend themselves more to wide field radiation or chemotherapy.

## 2. Brain Vascular Malformations

Brain Vascular Malformations can be further subdivided into **Arteriovenous Malformations** and **Cavernous Malformations**.

### BRAIN ARTERIOVENOUS MALFORMATIONS (AVM's)

Brain AVM's are abnormal tangles of blood vessels in the brain, that are usually thought to be present since birth. They can bleed, which can lead to serious consequences. They can also cause seizures. They bleed at a rate of about 3% per year and about half of these will lead to serious consequences. For the first year after a bleed, the bleed rate increases to about 6%. AVM's can vary in size, location, and presentation.

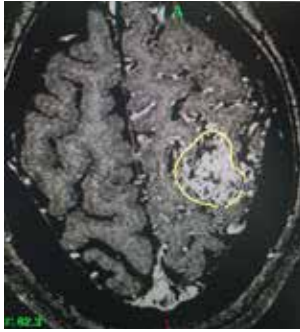
Very large AVM's are usually just observed. AVM's that are discovered in patients who are sick or elderly are also, usually, just watched. Surgery is best considered for AVM's that have bled, and are small and located in a superficial and non-eloquent location in the brain. Immediately prior to surgery, the AVM is usually “embolized”. This means that during an angiogram (a picture of the arteries taken with a catheter threaded up from the artery in the groin) material is injected into the AVM to reduce its blood supply to make the surgery safer. Very small AVM's that have bled may be completely obliterated with embolization. For most AVM's, Radiosurgery is the procedure of choice. The focused radiation causes the abnormal

blood vessels to clot off (“thrombose”) over time, usually 2-4 years. Once the vessels are fully thrombosed, there is no longer a risk of bleeding. Sometimes, if the entire AVM has not resolved after one Radiosurgery treatment, another treatment can be performed, years later, on the residual. Also, for some larger AVM's, treatments can be “staged”, that is, part of the AVM can be treated in one Radiosurgery treatment, and then, the remainder can be treated in a second session, months later.

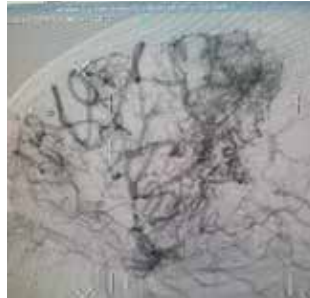
#### Other types of abnormal arterial - venous connections (Fistulae):

1. A **Cavernous-Carotid Fistula (CCF)** is an abnormal connection between the carotid artery and the cavernous sinus, a complex of veins behind the eye. These can cause double vision and redness of the eye. They are usually treated with embolization, but if this is not successful, Radiosurgery can be used.
2. A **Dural Arterio-Venous Fistula (DAVF)** is an abnormal connection between an artery and vein in the dura, the covering layer of the brain. These can cause bleeding in the brain, and are also usually treated with embolization. If this is not successful or feasible, Radiosurgery can be used.

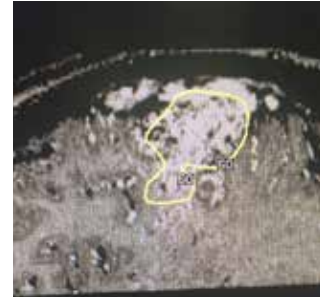




At Treatment

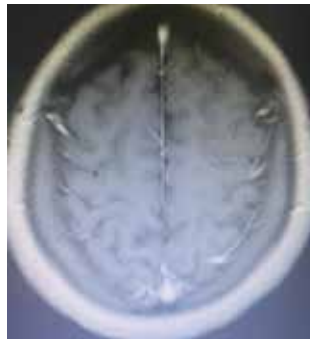


At Treatment

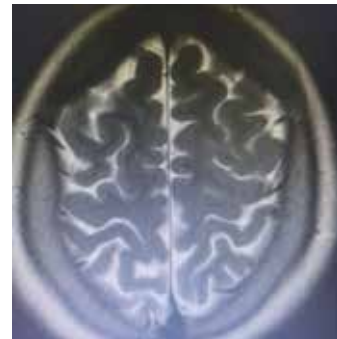

### AVM Case Study #1

This is a 13 year old girl who was experiencing right arm and leg tingling episodes and headaches, found to have a moderate sized left frontal AVM. Gamma Knife was performed. An MRI done 6 years later shows complete resolution of the AVM. Her symptoms have all resolved.

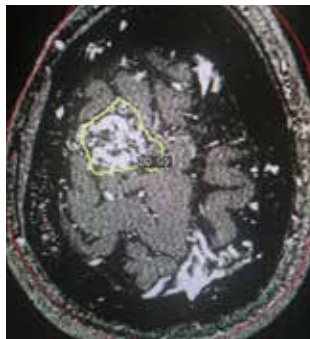


After Treatment

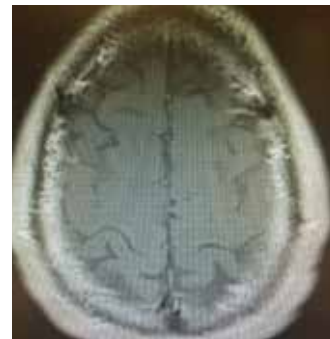

### AVM Case Study #2

This is a 28 year old man who presented with headaches, found to have a 2.5cm right frontal avm. Gamma knife was performed. 3 years later, the avm is gone and he has no symptoms.



At Treatment



After Treatment

## BRAIN CAVERNOUS MALFORMATIONS

Cavernous Malformations (CM's) of the brain are small abnormalities that are usually congenital that can cause small areas of local bleeding. They can also cause seizures. They frequently produce no symptoms, and are then just observed. If a cavernous malformation produces symptoms (like a seizure or a symptomatic bleed in the brain) and can be safely removed, then surgery is usually performed. If a CM has caused a symptomatic bleed and is in a location that would be difficult to remove surgically (such as the brainstem or basal ganglia) then Radiosurgery can be used, and does reduce the likelihood of future bleeding.

### 3. Brain Functional Disorders

Functional Brain Disorders are, in general, diseases in brain function that can be improved by injuring or modulating normal brain tissue. These disorders include **Pain Disorders, Movement Disorders, and Epilepsy/Seizure Disorders.**

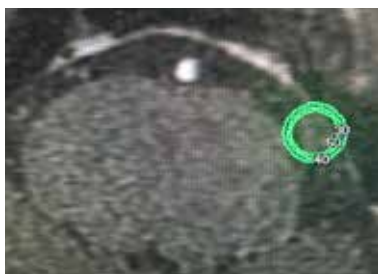
#### PAIN DISORDERS

##### 1. Trigeminal Neuralgia

Trigeminal Neuralgia (TN) is a condition in which people get sudden, brief, sharp, severe, electric shock or stabbing pains on one side of the face that are often triggered by light touch of the face, and usually respond to antiseizure medicines like tegretol and neurontin. The cause is usually a small blood vessel pressing on the trigeminal nerve (fifth cranial nerve), but TN can also be caused by multiple sclerosis (MS), or a small tumor contacting the trigeminal nerve.

For young healthy people who cannot be adequately managed with medicines and who do not have MS, surgery to move the blood vessel away from the nerve, a Microvascular Decompression ( "MVD") is usually recommended. For people who are older, or have significant medical co-morbidities, or who have MS, or

who have had an MVD already, a "nerve injuring procedure" is usually recommended. These are outpatient procedures, that, by injuring the trigeminal nerve a bit, can also give pain relief. These techniques include injuring the nerve with a "nerve block" or "rhizotomy", done by an injection through the cheek, or by radiosurgery which can also target the trigeminal nerve within the brain. The nerve injuring techniques are generally lower risk procedures. However, compared with the MVD, they have more chance of symptom recurrence, because the nerve will regrow and heal with time, and also more chance of causing some new numbness or achiness in the face. The numbness can occur because the nerve is being deliberately injured. If it does occur, it is usually mild and usually improves with time as the nerve regrows and heals. Radiosurgery for TN usually takes a few weeks to work. Gamma Knife can be repeated after the first treatment, if needed. Trigeminal Neuralgia is one of the more common indications for Radiosurgery, after brain tumors.



At Treatment



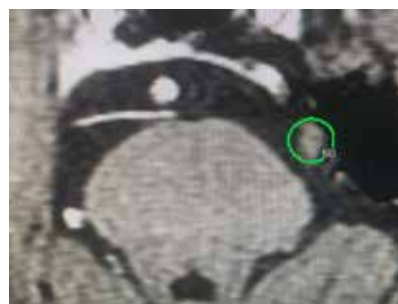
At Treatment

##### Trigeminal Case Study #1

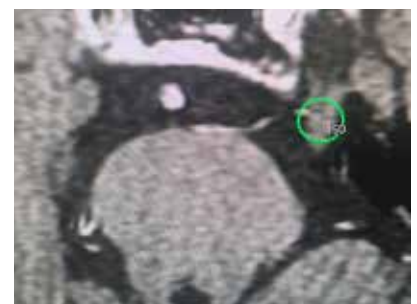This is a 60 year old man with medically refractory left trigeminal neuralgia in a V2 distribution. He had an unsuccessful percutaneous trigeminal rhizotomy elsewhere. He had a history of coronary artery disease and a triple bypass. Gamma Knife was performed. 14 years later, he remains pain free, with no numbness and requiring no medications.

##### Trigeminal Case Study #2

This is a 59 year old woman with MS and left V3 distribution medically refractory trigeminal neuralgia. She underwent Gamma Knife treatment, which gave good relief of pain for one year. The pain recurred and she then underwent a repeat Gamma Knife treatment. 6 years later she remains pain free, with no numbness, and on no medication for the trigeminal neuralgia.



At First Treatment



At Second Treatment

## 2. Glossopharyngeal Neuralgia

Glossopharyngeal Neuralgia (GPN) is a condition in which people get sudden, brief, severe, electric shock or stabbing pains on one side of the deep ear or throat region. These pains are often triggered by swallowing and usually respond to antiseizure medicines like tegretol and neurontin. GPN is very similar to Trigeminal Neuralgia, except that it involves the Glossopharyngeal nerve, the 9<sup>th</sup> cranial nerve (and possibly the upper part of the Vagus nerve, the 10<sup>th</sup> cranial nerve) instead of the trigeminal nerve, the 5<sup>th</sup> cranial nerve. Like trigeminal neuralgia, it is usually caused by a blood vessel contacting the nerve inside the brain. It is much less common than Trigeminal Neuralgia.

For young healthy people who have failed medicine, the treatment is usually surgery to cut the 9<sup>th</sup> and upper 10<sup>th</sup> nerves, and or, to move a blood vessel away from those nerves. For older patients, or patients with medical problems, Radiosurgery can be performed, targeting the 9<sup>th</sup> and 10<sup>th</sup> nerves inside the brain.

## MOVEMENT DISORDERS

### 1. Tremor

Tremor is a movement disorder that is first treated with medicines. If medicines fail, tremor can be treated by injuring one of the nuclei of the thalamus in the brain. It can also be treated with surgery (“deep brain stimulation”) that stimulates the same thalamic nucleus and can essentially deactivate it, causing relief of tremor. Radiosurgery can also accomplish this same task (Radiosurgery Thalamotomy). Of interest, a similar non-invasive thalamotomy technique that is also being used now is thalamotomy with MRI guided Focused Ultrasound (MRgFUS). Radiosurgery thalamotomy will only treat tremor symptoms, and only on one side of the body. This would be ideally suited to someone who had severe “essential tremor” (tremor not due to other causes), worse on one side of the body, and refractory to medical management, particularly if the person was not a good candidate for open surgery. If the tremor was bad on both sides, Radiosurgery could be performed, first on the one side, and then

later, on the other. Patients with Parkinson’s Disease are usually not ideal candidates for this treatment because they usually have many other movement disorder problems besides just the tremor. Nonetheless, if tremor is the dominant feature, this procedure can be considered.

## EPILEPSY

Epilepsy is caused by an abnormal misfiring of nerve cells in the brain. Sometimes, this misfiring remains a local phenomenon with a temporary local shaking or loss of partial brain function (“focal seizure”), and sometimes it spreads throughout the brain causing generalized convulsions and loss of consciousness (“generalized seizure”).

### 1. Medial Temporal Lobe Epilepsy

One of the most common locations for a seizure to arise is the medial temporal lobe. In these cases, if medicines are not adequately controlling seizures, surgical removal of the medial temporal lobe can eliminate the seizures. A newer technique of inserting a tiny laser into the temporal lobe to injure the structures (Laser Interstitial Thermal Therapy, or LiTT), has also been effective. Radiosurgery has been investigated as an alternative to open surgery. The thought was that by treating these same structures with focused radiation, this could also cause the seizures ultimately to stop. However, to date, Radiosurgery has not seemed to be as effective as surgical options.

### 2. Epilepsy Targets Outside the Temporal Lobe

Other targets outside the temporal lobe have also been considered for Radiosurgery. These include the seizure focus as well as the connecting tissue between the right and left sides of the brain that allows for secondary generalization of the seizures, the “corpus callosum”. Nonetheless, at this point, these procedures are only used very infrequently, and more investigation would be useful.



## Clarifying some important points about radiosurgery:

1. **Radiosurgery can be used for patients with benign disease.** While standard radiation is usually not used for benign diseases, Radiosurgery, by superfocusing the radiation, acts by a different mechanism, and can treat benign disease, like benign tumors, and vascular malformations.
2. **Radiosurgery can be used in children.** While most indications for Radiosurgery occur in adults, there are some circumstances for which Radiosurgery can be used safely and effectively for children. For example, a child with a deep brain AVM that had bled that was not surgically accessible would be a good candidate for Radiosurgery. The long term risk of radiation from Radiosurgery is limited in both children and adults because of the superfocused nature of the radiation delivered.
3. **Radiosurgery can be used for patients with “radioresistant cancers”.** While standard radiation usually is not that effective for certain “radioresistant cancers”, Radiosurgery, because it acts differently, can be very effective for these types of tumors.
4. **Radiosurgery can be effective even if the tumor does not shrink in size.** Sometimes, Radiosurgery causes a tumor to stabilize or just mildly shrink, but, so long as the tumor does not continue to grow, this may still be an excellent and effective treatment.
5. **Radiosurgery can be used for multiple tumors.** Sometimes a person may have more than one tumor that needs to be treated, such as in the case of brain metastases. Radiosurgery can often be used on even 10 tumors at a time.
6. **Radiosurgery can be used for large tumors or masses.** While generally one wants to limit the size of a Radiosurgery target, depending on the circumstances, larger masses can often still be treated with Radiosurgery either by lowering the dose, or using multiple fractions, or staging the treatment in 2 or 3 sessions, or utilizing a combination of these techniques.
7. **Radiosurgery can be repeated.** Standard radiation often cannot be repeated to a given area because the normal tissues have already been exposed to the maximum tolerated dose. Radiosurgery, however, usually can be repeated, depending on the circumstances, because the surrounding tissues are usually exposed to a fairly limited amount of radiation.
8. **Radiosurgery can be used in the setting of “edema”.** Even if there is some swelling of the surrounding tissues, such as brain swelling in the setting of metastases, Radiosurgery can usually still be performed. Oral steroids can usually decrease the swelling until the Radiosurgery can take effect.
9. **Radiosurgery can be used without a “tissue diagnosis”.** Usually one wants to be fairly confident of the diagnosis before performing Radiosurgery. However, this diagnosis rarely requires a “biopsy” , that is, a surgical procedure to obtain diseased tissue for pathological confirmation. In most cases, the diagnosis for Radiosurgery is fairly clear from the imaging and past history.

### Summary

Brain Radiosurgery involves delivery of a super-focused, highly conformal, outpatient radiation treatment, that can effectively treat many diseases of the brain, with minimal risk. In many cases, Radiosurgery is as effective as traditional surgery, with a much lower risk profile. Radiosurgery can be very effective for Brain Tumors (benign and malignant), Brain Vascular malformations, and Functional Brain Disorders, such as Trigeminal Neuralgia.




# NSPC Brain & Spine Surgery

Neurological Surgery, P.C.

100 Merrick Road • Suite 128W  
Rockville Centre, NY 11570

Join us on Facebook, Twitter, LinkedIn and YouTube! Visit [www.nspc.com](http://www.nspc.com) and click through.



## MICHAEL H. BRISMAN, M.D., F.A.C.S. Neurosurgeon

After receiving his undergraduate degree with high honors in Biology from Harvard University, Dr. Brisman obtained his medical degree from Columbia College of Physicians and Surgeons. He then completed a General Surgery internship and Neurological Surgery Residency at The Mount Sinai Medical Center in New York City.

Board certified by the American Board of Neurological Surgeons and a Fellow of the American College of Surgeons, Michael H. Brisman, M.D., specializes in the treatment of brain tumors and trigeminal neuralgia. He has performed over 1,000 radiosurgery procedures. He serves as the Co-Medical Director of the Long Island Gamma Knife® Center at South Nassau Communities Hospital and he has served as the Chief of Neurosurgery and Co-Director of the Neuroscience Institute at NYU-Winthrop Hospital. In addition, Dr. Brisman has formerly served as President of both the Nassau County Medical Society and the New York State Neurosurgical Society.

[nspc.com](http://nspc.com)

### Dr. Brisman Treats:

- Trigeminal Neuralgia
- Brain Tumors
- Pituitary Tumors
- Acoustic Neuromas
- Meningiomas
- Brain Metastases
- Gliomas
- Brain AVMS
- Hemifacial Spasm
- Glossopharyngeal Neuralgia
- Skull Tumors

### Dr. Brisman is proficient in the use of minimally invasive neurosurgical procedures including:

- Stereotactic Radiosurgery
- Gamma Knife®
- CyberKnife®
- Novalis Tx®
- Microvascular Decompression
- Neuroendoscopy
- Transsphenoidal Surgery
- Stereotactic-guided Craniotomy
- Stereotactic Brain Biopsy
- Percutaneous Trigeminal Rhizotomy