

REVIEW ARTICLE

MEDICAL PROGRESS

Cerebral Aneurysms

Jonathan L. Brisman, M.D., Joon K. Song, M.D., and David W. Newell, M.D.

From the Department of Cerebrovascular and Endovascular Neurosurgery, New Jersey Neuroscience Institute, JFK Medical Center, Edison, N.J. (J.L.B.); the Department of Endovascular Surgery, Institute for Neurology and Neurosurgery, Roosevelt Medical Center, New York (J.K.S.); and the Department of Neurosurgery, Seattle Neuroscience Institute, Swedish Medical Center, Seattle (D.W.N.). Address reprint requests to Dr. Brisman at the Department of Cerebrovascular and Endovascular Neurosurgery, New Jersey Neuroscience Institute at JFK Medical Center, Edison, NJ 08818, or at jbrisman@solarishs.org.

N Engl J Med 2006;355:928-39.
Copyright © 2006 Massachusetts Medical Society.

SACCULAR INTRACRANIAL ANEURYSMS, ABNORMAL FOCAL OUTPOUCHINGS of cerebral arteries, cause substantial rates of morbidity and mortality. Recently, major changes have occurred in the way we think about and treat this disease. Previous concepts about the natural history, particularly the risk of rupture of certain aneurysms, have been challenged.^{1,2}

When this topic was the subject of a Medical Progress article in the *Journal* in 1997, minimally invasive percutaneous endovascular treatment of intracranial aneurysms (a technique known as coiling) had been introduced as an experimental procedure for patients who were not good candidates for surgery.³ After almost a decade of increased use and evaluation, endovascular coiling has proved to be a safe and durable alternative to the traditional neurosurgical treatment of craniotomy and clip ligation (“clipping”). Coiling has now surpassed clipping as the primary method of treatment for intracranial aneurysms in some centers. Since the Guglielmi detachable coil for the treatment of intracranial aneurysms was approved in 1995 by the Food and Drug Administration (FDA), an estimated 150,000 patients have been treated with this device.^{4,5} In this article, the technological advances and supporting research contributing to this important change in practice patterns are reviewed.

EPIDEMIOLOGY AND PATHOPHYSIOLOGY

Intracranial aneurysms are common lesions; autopsy studies indicate a prevalence in the adult population between 1 and 5 percent,² which translates to 10 million to 12 million persons in the United States.³ Fortunately, most aneurysms are small, and an estimated 50 to 80 percent of all aneurysms do not rupture during the course of a person’s lifetime.⁶ Intracranial aneurysms are considered to be sporadically acquired lesions, although a rare familial form has been described.³ Associated conditions include autosomal dominant polycystic kidney disease, fibromuscular dysplasia, Marfan’s syndrome, Ehlers–Danlos syndrome type IV, and arteriovenous malformations of the brain. An estimated 5 to 40 percent of patients with autosomal dominant polycystic kidney disease have intracranial aneurysms,^{3,7} and 10 to 30 percent of patients have multiple aneurysms.³ Screening with intracranial magnetic resonance angiography is indicated for people who have two immediate relatives with intracranial aneurysms and for all patients with autosomal dominant polycystic kidney disease.^{3,8,9} Rescreening of patients with autosomal dominant polycystic kidney disease is recommended, although the frequency of the procedure depends on whether other affected family members are known to have intracranial aneurysms.⁸

The estimated incidence of subarachnoid hemorrhage from a ruptured intracranial aneurysm in the United States is 1 case per 10,000 persons, yielding approximately 27,000 new cases of subarachnoid hemorrhage each year.^{3,5} Subarachnoid hemorrhage is more common in women than in men (2:1)¹⁰; the peak incidence

is in persons 55 to 60 years old.¹¹ An estimated 5 to 15 percent of cases of stroke are related to ruptured intracranial aneurysms.¹² Aneurysmal subarachnoid hemorrhage, a form of hemorrhagic stroke, has a 30-day mortality rate of 45 percent. An estimated 30 percent of survivors will have moderate-to-severe disability.¹³

Little is known about the cause of intracranial aneurysms or the process by which they form,

grow, and rupture, although hypertension and smoking-induced vascular changes are thought to have a major role.³ The most common histologic finding is a decrease in the tunica media, the middle muscular layer of the artery, causing structural defects. These defects, combined with hemodynamic factors, lead to aneurysmal out-pouchings at arterial branch points in the subarachnoid space at the base of the brain (Fig. 1).³

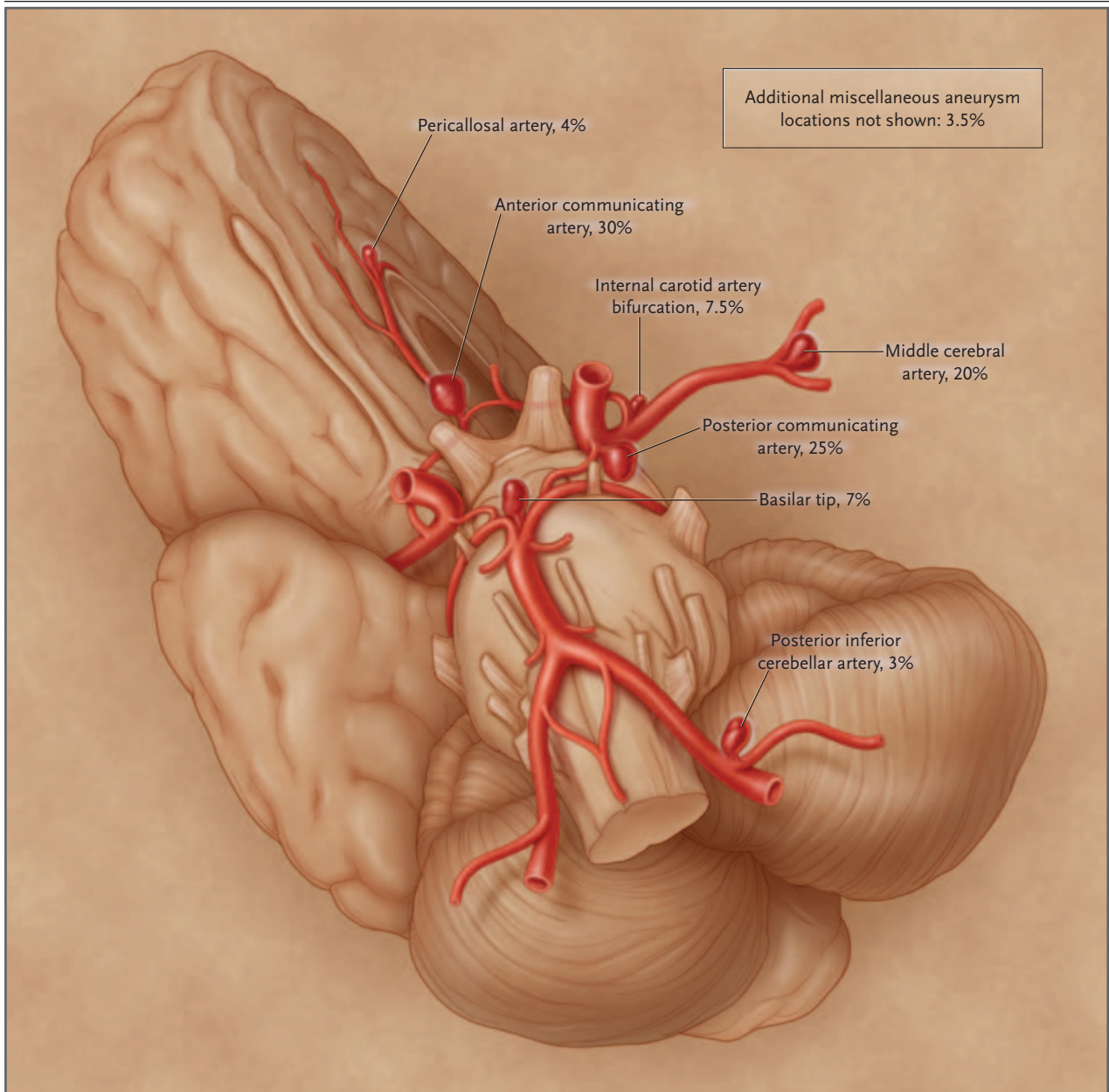


Figure 1. The Intracranial Vasculature, Showing the Most Frequent Locations of Intracranial Aneurysms.

Percentages indicate the incidence of intracranial aneurysms.

NATURAL HISTORY AND RISK
OF RUPTURE

The most common presentation of intracranial aneurysm is rupture leading to subarachnoid hemorrhage.¹¹ At present, aneurysms are increasingly detected before rupture, given the increased availability and improved sensitivity of noninvasive imaging techniques. An unruptured aneurysm may be asymptomatic and thus be found incidentally, or it may be diagnosed on the basis of symptoms. Unruptured aneurysms cause symptoms by exerting a mass effect, leading to cranial-nerve palsies or brain-stem compression.⁶ One common aneurysm-related syndrome is rapid onset of a third-nerve palsy caused by enlargement of an aneurysm of the posterior communicating artery.³

Aneurysms presenting with subarachnoid hemorrhage tend to bleed again. Two to 4 percent hemorrhage again within the first 24 hours after the initial episode, and approximately 15 to 20 percent bleed a second time within the first two weeks.¹¹ Persons with intracranial aneurysms presenting with symptoms of compression such as cranial-nerve palsies or brain-stem dysfunction should be evaluated and treated promptly because of the increased risk of rupture (6 percent per year)¹⁴ in this subgroup.⁶ The risk of rupture of an intracranial aneurysm that has not bled but is found incidentally is much less certain, and these intracranial aneurysms are generally managed electively. In the past, unruptured intracranial aneurysms were viewed as posing a high risk, with an estimated risk of rupture of approximately 1 to 2 percent per year.¹⁵⁻¹⁸ Before the availability of detachable coils, most intracranial aneurysms were surgically clipped to prevent rupture.¹⁹⁻²¹

In 1998, the results of a retrospective study involving 53 centers and 2621 subjects challenged the traditional thinking about the risk of rupture of unruptured intracranial aneurysms.¹ In this large cohort of people with unruptured aneurysms selected for conservative treatment, the rate of rupture for certain small aneurysms (less than 10 mm in diameter) was found to be as low as 0.05 percent per year. Among patients with a history of a bleeding aneurysm, the risk of hemorrhage was 10 times that of patients who had no such history. Intracranial aneurysms larger than 10 mm and aneurysms of the basilar apex or posterior communicating artery had an even higher rate of rupture. The prospective part of the

study (the International Study of Unruptured Intracranial Aneurysms), in which 1692 patients selected for conservative treatment were followed, yielded similar results. However, the stratification was slightly different; the subgroup with the smallest aneurysms — 7 mm or less (which included 62 percent of the cohort) — had a five-year cumulative rate of rupture of 0 percent.² A major objection to that multicenter study is that the subjects entered into the study were those preselected by surgeons for observation on the basis of their opinion that these aneurysms were less likely to rupture.^{22,23} Subsequent studies have shown higher risks of rupture for unruptured intracranial aneurysms.^{24,25}

MEDICAL DIAGNOSIS
AND MANAGEMENT
OF SUBARACHNOID HEMORRHAGE

CLINICAL PRESENTATION AND DIAGNOSIS

Many patients with subarachnoid hemorrhage present with an acute onset of severe headache, often described by patients as the “worst headache of my life.” However, an estimated 10 percent die before reaching medical attention, and many others present in a coma or with severe neurologic compromise.⁵ Clinical grading scales such as the Hunt and Hess Scale (Table 1) are used to describe the neurologic condition on admission and are considered good predictors of ultimate outcome.^{26,27} Computed tomography (CT) of the head without the administration of contrast material is the initial diagnostic test of choice for suspected subarachnoid hemorrhage. The Fisher grade uses a four-point scale to describe the amount of blood on non-contrast-enhanced CT

Table 1. Hunt and Hess Grading Scale for Subarachnoid Hemorrhage.

Grade	Clinical Description
1	Asymptomatic or minimal headache and slight nuchal rigidity
2	Moderate-to-severe headache, nuchal rigidity, and no neurologic deficit other than cranial-nerve palsy
3	Drowsiness, confusion, or mild focal deficit
4	Stupor, moderate-to-severe hemiparesis, and possibly, early decerebrate rigidity and vegetative disturbances
5	Deep coma, decerebrate rigidity, and moribund appearance

of the head and has been shown to correlate with the development of vasospasm.²⁸ Lumbar puncture is reserved for the approximately 5 percent of patients in whom cranial CT reveals no abnormalities, despite a history suggesting a subarachnoid hemorrhage.¹¹ Bloody cerebrospinal fluid that fails to clear with continued egress of cerebrospinal fluid should raise a suspicion of subarachnoid hemorrhage. The presence of xanthochromia, a yellowish discoloration of the cerebrospinal fluid representing bilirubin from the breakdown of hemoglobin, is even more definitive than a high red-cell count in the cerebrospinal fluid. Blood from a subarachnoid hemorrhage that occurred more than 12 hours before the spinal tap will result in xanthochromic cerebrospinal fluid, whereas fresh blood, as might occur with a traumatic spinal tap, will not.²⁹

The next step after making a definitive diagnosis of a spontaneous subarachnoid hemorrhage should be to determine whether an aneurysm is the cause. To do so, it is important to select the best imaging method for a given patient.

IMAGING METHODS AND OPTIONS

The three methods of choice to identify or rule out an intracranial aneurysm and to delineate the size and morphologic features of an intracranial aneurysm are CT angiography (CTA) after a venous injection, magnetic resonance angiography (MRA), and angiography by direct intraarterial catheterization (catheter angiography); the last is still considered the benchmark. Several studies have evaluated the accuracy of detecting intracranial aneurysms by comparing CTA, MRA, and the synergistic combination of CTA and MRA with catheter angiography, intraoperative findings, or both.³⁰⁻³⁵

CTA provides software-generated images from thin-section contrast-enhanced CT to show cerebral vessels in three-dimensional views. The reconstructed pictures, which are obtained in minutes, can be rotated and allow the vasculature to be visualized relative to the brain and the bones of the skull base, facilitating surgical planning. Studies evaluating CTA in the management of intracranial aneurysms have reported sensitivities ranging from 0.77 to 0.97 and specificities ranging from 0.87 to 1.00.^{12,30,31,33,36,37} Sensitivity drops precipitously for the detection of smaller aneurysms; sensitivity for aneurysms smaller than 3 mm is estimated to be 0.40 to 0.91.^{30,32,38} Cau-

tion must be exercised when CTA is used in patients with impaired renal function, since a large bolus of contrast material is administered.

MRA takes considerably longer to perform than does CTA (roughly 30 to 60 minutes) and is thus more difficult to use in critically ill patients. MRA is both highly sensitive and specific for the detection of intracranial aneurysms (sensitivity, 0.69 to 0.99; specificity, 1.00).^{12,33,36,35} The sensitivity of MRA, like that of CTA, diminishes for very small aneurysms (under 3 mm in diameter) and was 0.38 in one series.²⁸

In 1998, a three-dimensional form of catheter angiography was developed that permits reformatted images to be rotated. This advance over two-dimensional catheter angiography, known as three-dimensional rotational angiography, permits the aneurysm and its relation to other vessels to be assessed in three dimensions, overcoming prior imaging limitations.^{39,40} Catheter angiography, with or without the advanced three-dimensional capability, is more expensive and invasive than either MRA or CTA. Its risks, particularly in the hands of experienced operators, appear acceptably low (neurologic complications occurring in 1.0 to 2.5 percent of cases, with permanent impairment in 0.1 to 0.5 percent),⁴¹⁻⁴⁴ given the seriousness of intracranial aneurysms. Non-neurologic risks such as femoral-artery injury (0.05 to 0.55 percent), groin hematoma (6.9 to 10.7 percent), and adverse renal effects induced by contrast material and other allergic reactions (1 to 2 percent) are well known and often transient.⁴⁵ Elderly patients with atherosclerotic vessels or patients with impaired renal function would be more likely to have complications such as a thromboembolic event or nephrotoxicity, respectively.³

CLINICAL APPROACH TO IMAGING

High-quality catheter angiography is generally definitive. Thus, it is the test of choice to evaluate subarachnoid hemorrhage,¹² although CTA alone has been used.⁴¹ Because of the less invasive nature of CTA and MRA, they are recommended as the first approaches in the evaluation of unruptured aneurysms.

Angiographic examination fails to disclose an aneurysm in 10 to 20 percent of cases of subarachnoid hemorrhage. In cases in which the results of angiography are negative, angiography is usually repeated in one to six weeks.^{26,46} The cause

of a subarachnoid hemorrhage without an identified aneurysm is unknown. Hypertensive rupture of a small artery or vein is one proposed mechanism. In these circumstances, an MRI of the brain and cervical spine is usually obtained after the administration of contrast material during the initial admission to rule out a thrombosed aneurysm, hemorrhagic tumor, spinal arteriovenous malformation, or dural arteriovenous fistula, although the diagnostic yield is small.

ACUTE EFFECTS OF SUBARACHNOID HEMORRHAGE

Hydrocephalus develops in about 15 to 20 percent of patients who have an aneurysmal subarachnoid hemorrhage.¹¹ Symptomatic hydrocephalus is usually treated with ventriculostomy and drainage of cerebrospinal fluid.

Cerebral vasospasm, a major cause of morbidity and mortality, refers to the intracranial vasoconstriction that may occur between 3 and 12 days after a subarachnoid hemorrhage. The cause of vasospasm is unknown; even with maximal therapy, vasospasm can cause strokes and death.¹¹ Transcranial Doppler ultrasonography is a useful noninvasive method to detect vasospasm.

MEDICAL THERAPY

Medical treatment consists of orally administered nimodipine (60 mg every four hours for 21 days), which has been shown to improve the outcome after subarachnoid hemorrhage.⁴⁷ In patients who have a clear increase in the transcranial Doppler velocities or in whom new neurologic deficits develop, triple-H (hypertension, hypervolemia, and hemodilution) therapy is initiated. Goals of this treatment include a hematocrit of 30 percent, a central venous pressure of 8 to 12 mm Hg, and enough artificially induced hypertension to prevent or reverse new neurologic deficits.^{5,11,26} Such deficits usually correlate with the vascular territory of the vessel in spasm and may be as subtle as a decrease in the level of arousal or as overt as a new hemiparesis. In light of the risks of triple-H therapy, such as cardiac dysfunction, catheter angiography is occasionally used to confirm the findings on transcranial Doppler examination.

Patients with any persistent new neurologic deficit who have no response to medical treatment should undergo urgent catheter angiography to confirm the presence of vasospasm, followed by angioplasty of the narrowed vessels or intraarterial administration of smooth-muscle relaxants

such as papaverine.^{48,49} Balloon angioplasty and antispasmodic agents result in angiographically confirmed arterial dilatation in a high percentage of patients (90 to 98 percent).^{49,50} Clinical improvement, however, does not invariably correlate with radiographic success. Some observers report a rate of neurologic improvement of 61 to 70 percent, whereas others report no benefit as compared with triple-H therapy.^{49,51,52}

Evidence of cardiac abnormalities after subarachnoid hemorrhage is common and includes electrocardiographic changes (25 to 100 percent of cases),^{53,54} elevations of cardiac enzymes (troponin in 17 to 28 percent and creatine kinase MB isoenzyme in 37 percent of cases),^{53,55-57} and left ventricular dysfunction (8 to 30 percent of cases).^{58,59} This combination of abnormalities, known as "cardiac stun," appears to result from excessive catecholamine release in response to the intracranial hemorrhage. The presence of a markedly decreased ejection fraction with motion abnormalities of the ventricular wall that do not match the electrocardiographic vascular distribution of ischemia helps to make the diagnosis.^{56,59} Levels of both creatine kinase MB isoenzyme and troponin are usually elevated, but the troponin elevation is generally only a 10th of that seen with true ischemic myocardium.⁵⁶ Most cases of cardiac stun are temporary; permanent myocardial injury appears to be rare, irrespective of whether early treatment of the aneurysm is performed.⁵³

TREATMENT OPTIONS

There are three options for treating intracranial aneurysms: observation, craniotomy with clip ligation (clipping) (Fig. 2), and endovascular occlusion with the use of detachable coils (coiling) (Fig. 3). All ruptured aneurysms in patients with Hunt and Hess grades 1 to 4 are treated early (generally within 72 hours). There is debate about how to treat patients with the most severe grade, Hunt and Hess grade 5; the historically high incidence of poor outcome despite treatment has prompted the suggestion of conservative management unless clinical improvement occurs. However, recent evidence supports the use of aggressive therapy for most of these patients, including placement of a ventricular drain and securing the aneurysm by clipping or coiling.²⁶ Detachable coils have been increasingly used as a less physiologically stressful alternative to clipping the aneurysm

in this subgroup of patients, who already have severe brain injury.²⁶

Intact aneurysms that are discovered incidentally are either observed or treated electively, depending on the patient and the size and state of the aneurysm. Observation consists of routine periodic follow-up imaging and physician visits to review the studies. Clipping of aneurysms requires the performance of a craniotomy by a neurosurgeon with the patient under general anesthesia. Permanent clips made from MRI-compatible alloys are placed across the neck of the aneurysm, excluding it from the circulation (Fig. 2).

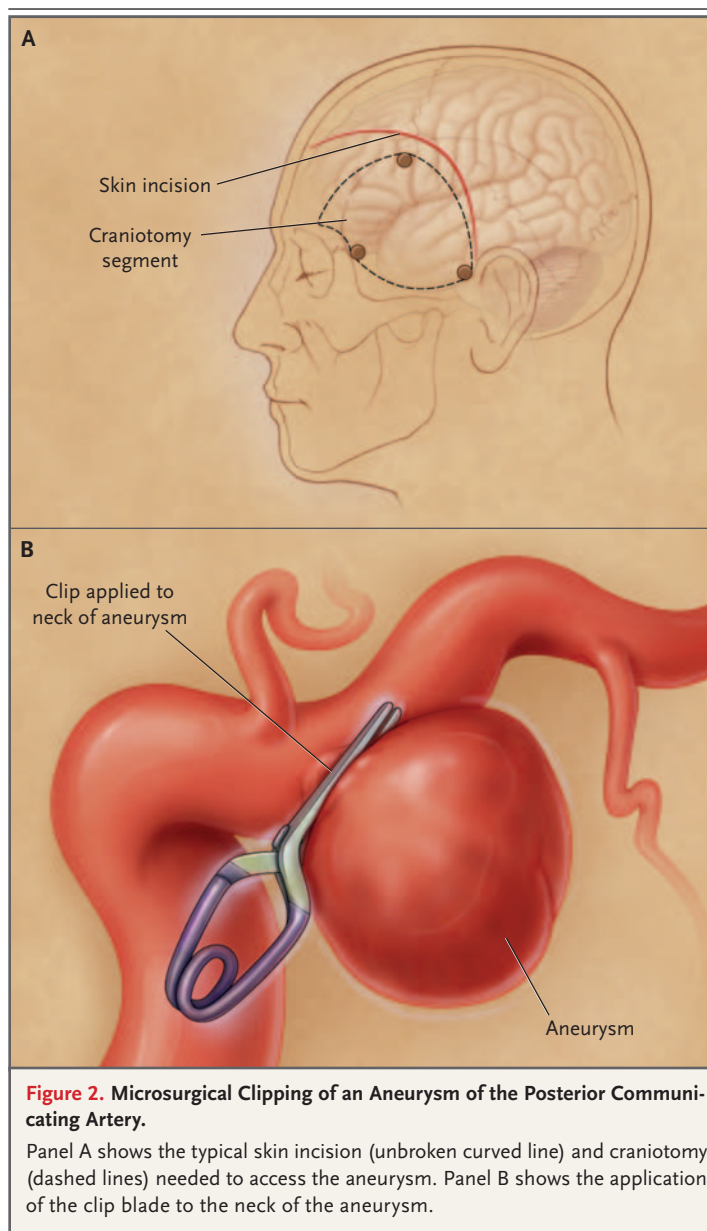
An interventional neuroradiologist, a neurosurgeon, or a neurologist with training in interventional radiology performs endovascular coiling.⁶⁰ General anesthesia is often used during the placement of detachable coils, although some centers prefer to use only sedation in order to monitor the patient's neurologic status during the procedure.⁶¹ Neurophysiological monitoring has been described as another way to monitor neurologic function during coiling.⁶² With the use of angiographic techniques, a microcatheter is advanced into the aneurysm, and detachable coils of various sizes and shapes are deployed to decrease the amount of blood or to stop blood from filling the aneurysm (Fig. 3).

COMPARISON OF CLIPPING AND COILING

Risks of Clipping

In one large, single-center series and two meta-analyses, the morbidity and mortality rates associated with clipping an unruptured aneurysm ranged from 4.0 to 10.9 percent and 1.0 to 3.0 percent, respectively.¹⁹⁻²¹ Although successful clipping is generally associated with definitive protection against rupture, long-term studies have documented a certain small risk of technical failure, incomplete occlusion (5.2 percent),⁶³ recurrence (1.5 percent), and hemorrhage (0.26 percent).⁶⁴

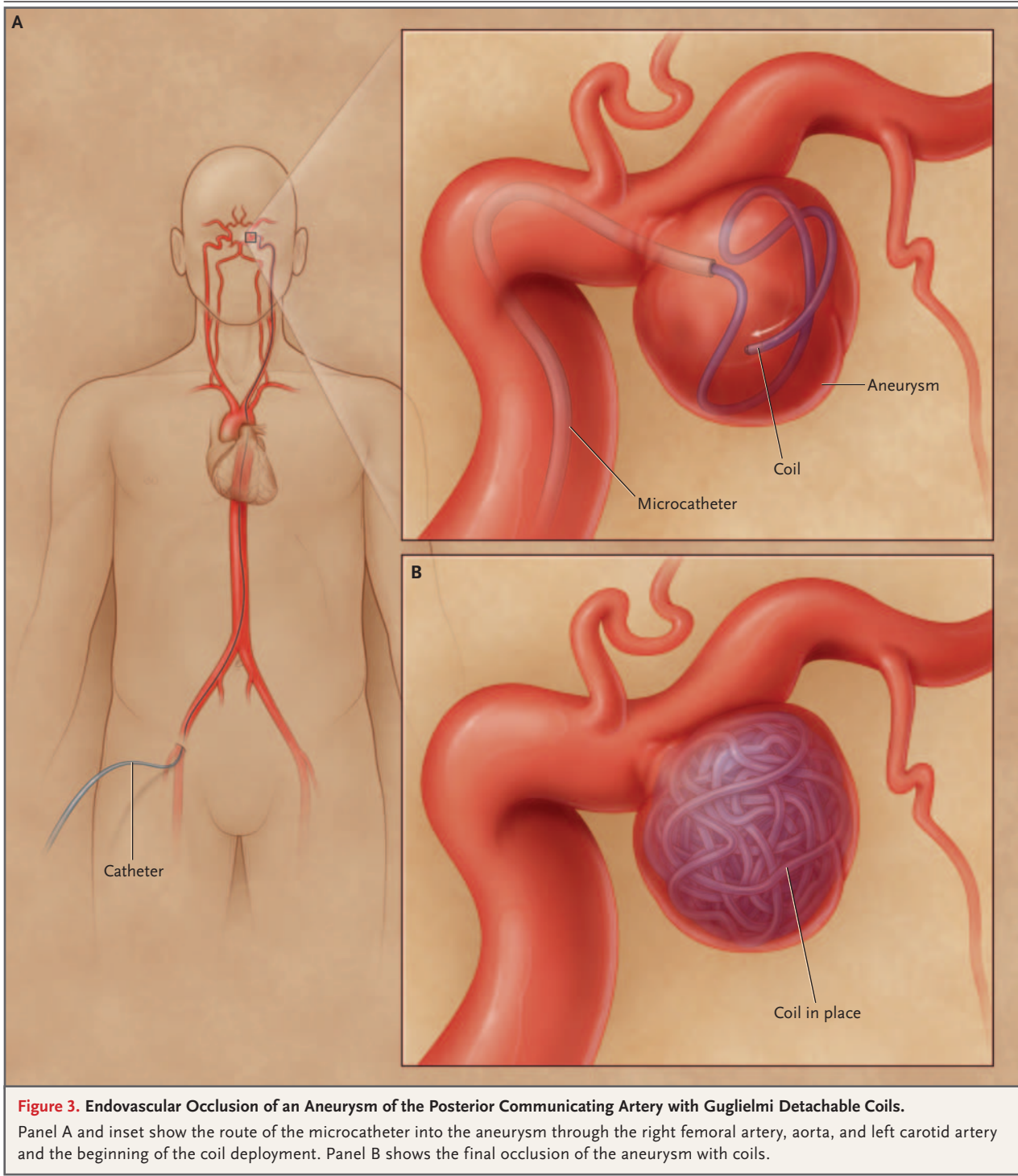
The International Study of Unruptured Intracranial Aneurysms assessed the risk of morbidity associated with the clipping of unruptured aneurysms. The risk associated with surgical repair was reported to be 15.7 percent after one year, higher than previously reported.¹ Additional single-center reports, however, have since demonstrated a lower risk of surgical morbidity, in the range of 3 to 7 percent.⁶ In any event, the results of the International Study of Unruptured Intracranial Aneurysms have had an important



effect on the management of unruptured aneurysms^{65,66}; more aneurysms are now treated with observation. Guidelines for the management of unruptured intracranial aneurysms were issued by the Stroke Council of the American Heart Association in 2000.¹²

Risks of Inserting Detachable Coils

Minor risks of inserting detachable coils, such as reactions to contrast material and groin hematomas, infections, or pseudoaneurysms, are similar to those of diagnostic catheter angiography.⁶⁷ Ma-



major risks include arterial dissection (0.7 percent), parent-artery occlusion (2.0 percent), and thromboembolic phenomena (2.4 percent).⁶⁸ Intraprocedural rupture of the aneurysm during catheter advancement into the aneurysm or coil place-

ment is one of the most serious complications; two large series and one meta-analysis cited an incidence of 1.4 to 2.7 percent, with an associated mortality rate of 30 to 40 percent.⁶⁸⁻⁷⁰ Even lower rates of intraprocedural rupture (1 percent)

have recently been reported in one high-volume center; in that report, the associated morbidity was low (17 percent) and the mortality rate was 0 percent, perhaps reflecting increasing familiarity and experience with coils after approval by the FDA in 1995.⁷¹ Overall procedural morbidity and mortality rates for coiling have been reported as 3.7 to 5.3 percent and 1.1 to 1.5 percent, respectively.^{72,73} It is not feasible to perform a coiling procedure for some aneurysms (5 to 14.5 percent of cases),^{68,74} because unusual tortuosity of the vessels renders access difficult or because the contours of the aneurysm do not permit the coils to sit safely inside.

Recent technologic advances, including coils that are better able to conform in aneurysms with atypical morphology, balloons,⁷⁵ and intracranial stents, which were introduced in 2002 (Fig. 4),^{76,77} have markedly reduced the number of aneurysms that cannot be approached with the detachable-coil procedure. Importantly, there is a greater likelihood of partial occlusion when coils are used than when surgical clipping is used. In three single-center studies, 2868 subjects with intracranial aneurysms underwent a coiling procedure; successful angiographic occlusion (defined as >90 to 95 percent occlusion or a neck remnant only) was achieved in 85 to 90.4 percent of lesions. Larger aneurysms and aneurysms with wider necks typically had lower rates of successful occlusion.^{68,72,78}

Aneurysms that have been treated with coils may recur, and with recurrence, they have the potential to hemorrhage. Over time, blood flow can compress the coils within the aneurysm, a process known as compaction; as a result, the aneurysm may refill with blood, a process referred to as recurrence, or recanalization (Fig. 4). Recanalization rates appear to be in the range of 20.9 to 33.6 percent.⁷⁹ The importance of recurrence is unknown; also unknown is whether a partially coiled aneurysm is protected. Vigilant follow-up angiography is needed to detect aneurysms that recanalize,^{78,79} since re-coiling may be indicated and is safe (there were no complications in 53 aneurysms that underwent re-coiling in one study).⁸⁰ The risk of hemorrhage from a coiled aneurysm is thus higher than after confirmed clip ligation, but it is still very small; one large study documented a risk of 0.8 percent, with a mean (\pm SD) follow-up of 31.32 ± 24.96 months.⁷⁹

A promising solution to the problem of recur-

rence after coiling is the advent of biologically active coils that are impregnated with substances intended to interface with the vessel endothelium and form a collagenous matrix at the entrance of the aneurysm.⁸¹ Another new type of coil^{77,82} that expands once inside the aneurysm to induce denser packing appears to reduce the incidence of coil compaction in animal models.⁸³ Another potential solution to recanalization is a new flexible, self-expandable, microcatheter-delivered, nitinol stent (Neuroform stent, Target Therapeutics/Boston Scientific) (Fig. 4). This intracranial stent, which was recently approved by the FDA, is placed within the artery from which the aneurysm arises, thereby blocking it.^{76,77}

Relative Risks of Coiling and Clipping

Several retrospective studies⁸⁴⁻⁸⁶ suggest that despite its attendant risks, treating most ruptured and unruptured intracranial aneurysms with detachable coils appears to be safer than clipping, at least during the perioperative period. In separate reviews of a database of a university health system consortium (60 universities),⁸⁶ the California statewide database of hospital discharges,⁸⁵ and the hospital database of the University of California at San Francisco,⁸⁴ Johnston et al. reported that outcomes associated with clipping were worse than those associated with detachable coils. They also reported that the use of coils was associated with a lower rate of inpatient mortality, shorter hospital stay, and lower treatment costs.⁸⁴⁻⁸⁶

More robust data favoring the safety of coiling over clipping are available for aneurysms presenting with subarachnoid hemorrhage from a large, multicenter prospective study conducted in England.⁸⁷ In the International Subarachnoid Aneurysm Trial, 2143 patients presenting with a ruptured aneurysm were prospectively randomly assigned to either clipping or coiling.⁸⁸ A planned interim analysis of the data-monitoring committee indicated a rate of 23.7 percent for neurologic incapacity (dependency) or death in the endovascular cohort, as compared with 30.6 percent in the surgical group; recruitment into the trial was immediately stopped, since the relative risk (22.6 percent) and the absolute risk (6.9 percent) of dependency and death in the group assigned to coiling was clearly reduced as compared with that in the group assigned to clipping. These observations were upheld in the one-year follow-up

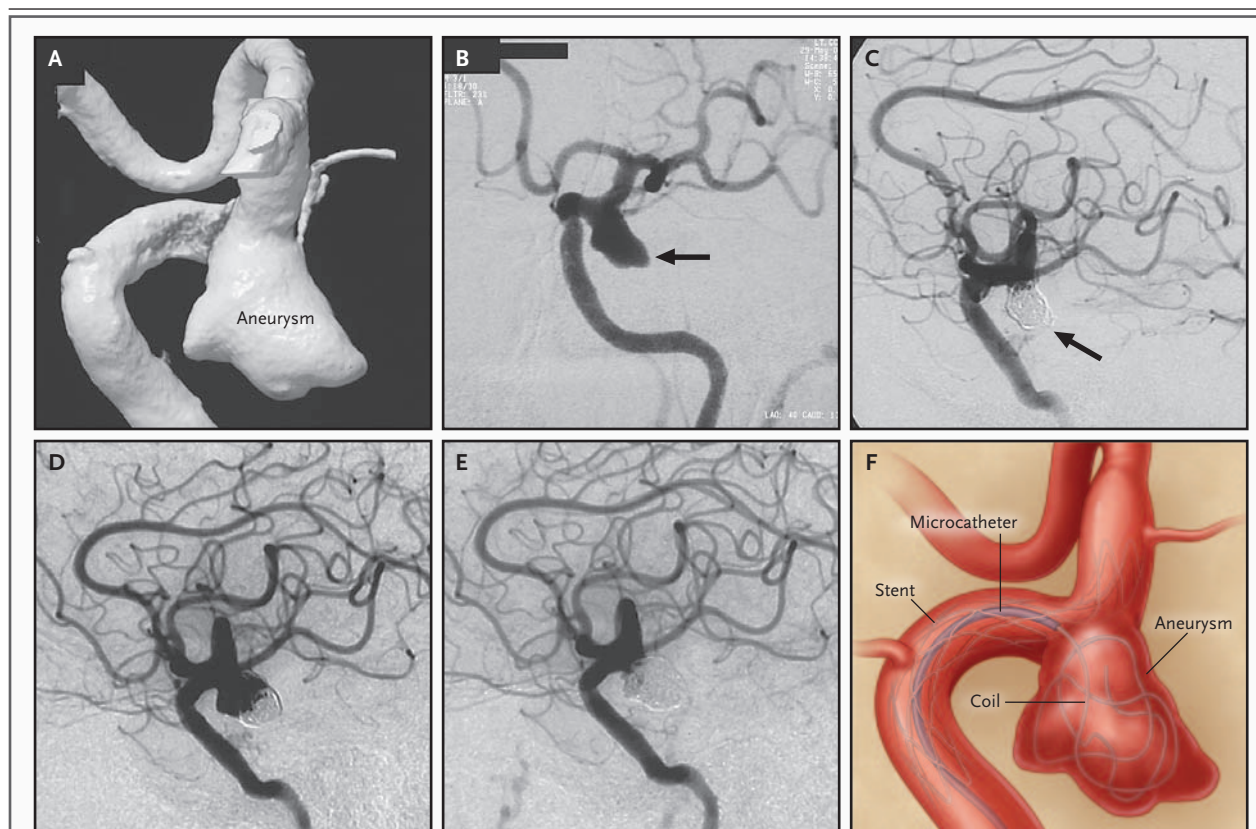


Figure 4. Stent-Assisted Re-Coiling after Recurrence of an Aneurysm Initially Treated with Coiling.

Panel A (three-dimensional rotational catheter angiogram) and Panel B (left carotid injection, two-dimensional catheter angiogram, oblique view) show an aneurysm of the posterior communicating artery (Panel B, arrow). Panel C (two-dimensional catheter angiogram, lateral view) shows the successful coiling of the aneurysm (arrow); this was followed eight months later with marked coil compaction and recanalization of the aneurysm (Panel D, two-dimensional catheter angiogram, lateral view). Panel E (two-dimensional catheter angiogram, lateral view) shows successful re-coiling of the aneurysm with the assistance of a stent (too small to visualize). Panel F shows the configuration used for the stent and the coil.

report on the patients who had been recruited and treated before the trial was stopped.⁸⁸

The results of this trial have had an important and lasting impact on the treatment of intracranial aneurysms.^{89,90} The American Society of Interventional and Therapeutic Neuroradiology⁹¹ and the American Association of Neurological Surgeons⁹² have responded to and critiqued the study in position statements, and the change in practice patterns engendered by the study has been reported.^{89,90} Several caveats, however, are worth noting. The study assessed 9559 patients with aneurysmal subarachnoid hemorrhage, but only a fraction of these patients were considered candidates equally suitable for clipping or coiling (inclusion criteria); thus, only 2143 patients (22.4 percent) underwent randomization. In addition,

most of the patients presented with a favorable clinical grade (>90 percent) and had aneurysms in the anterior circulation (97.3 percent) that were smaller than 10 mm (nearly 95 percent). Generalizing these findings to all intracranial aneurysms is not appropriate. Given the findings of the International Subarachnoid Aneurysm Trial, the American Society of Interventional and Therapeutic Neuroradiology recommends that all patients with ruptured intracranial aneurysms undergo independent evaluation and counseling by a physician capable of performing a detachable-coil procedure for aneurysms.⁹¹ The position statement of the American Association of Neurological Surgeons recommends surgical clipping as the treatment of choice, if an experienced vascular neurosurgeon believes it to be the best option.⁹²

THE EFFECTS OF SURGEON AND HOSPITAL VOLUME

Studies examining the outcomes of treatment of aneurysms as related to the experience of a particular surgeon, interventional radiologist, or institution indicate better outcomes when a high volume of procedures is performed.⁹³⁻⁹⁶ Most of these reports have been published by institutions and surgeons who have performed a high volume of procedures. One study reported better outcomes with surgeons who performed more than 30 craniotomies for aneurysms per year.⁹⁷ Such studies have prompted some observers to recommend regionalization of care for intracranial aneurysms.

OPTIMAL TREATMENT OF ANEURYSMS

The optimal management of both ruptured and unruptured intracranial aneurysms has not been fully determined. On the basis of the literature, it is important to consider the factors that support the treatment of an intracranial aneurysm with either surgical clipping or placement of detachable coils. In some cases either method is appropriate, and the decision may be influenced by difficult-to-quantify variables such as patient preference or operator availability or expertise.

Whether a given intracranial aneurysm should be observed, treated surgically, or managed endovascularly remains controversial. Ruptured intracranial aneurysms should be treated in a timely fashion to prevent a disastrous recurrence of hemorrhage; increasingly, the data support the use of coiling as a less invasive method for this purpose. Intracranial aneurysms that are incidentally discovered need not be treated in certain patients. Whether the increased durability afforded by clipping outweighs its slightly higher risks, as compared with those of coiling, remains to be determined.

Endovascular technology, despite its current limitations, is likely to continue to advance our ability to treat intracranial aneurysms. Both ongoing clinical trials, such as the International Subarachnoid Aneurysm Trial and the International Study of Unruptured Intracranial Aneurysms, and future randomized trials comparing clipping and coiling should shed light on the natural history of intracranial aneurysms along with the relative risks and benefits of observation as compared with interventions such as coiling and clipping.

No potential conflict of interest relevant to this article was reported.

REFERENCES

1. The International Study of Unruptured Intracranial Aneurysm Investigators. Unruptured intracranial aneurysms — risk of rupture and risks of surgical intervention. *N Engl J Med* 1998;339:1725-33. [Erratum, *N Engl J Med* 1999;340:744.]
2. Wiebers DO, Whisnant JP, Huston J III, et al. Unruptured intracranial aneurysms: natural history, clinical outcome, and risks of surgical and endovascular treatment. *Lancet* 2003;362:103-10.
3. Schievink WI. Intracranial aneurysms. *N Engl J Med* 1997;336:28-40. [Erratum, *N Engl J Med* 1997;336:1267.]
4. Endovascular repair of intracranial aneurysms. *Medtech Insight*. Vol. 7. No. 2. February 2005:47-52 (newsletter).
5. Wijdicks EF, Kallmes DF, Manno EM, Fulgham JR, Piepgras DG. Subarachnoid hemorrhage: neurointensive care and aneurysm repair. *Mayo Clin Proc* 2005;80:550-9.
6. Connolly ES, Solomon RA. Management of unruptured aneurysms. In: Le Roux PD, Winn HR, Newell DW, eds. *Management of cerebral aneurysms*. Philadelphia: Saunders, 2004:271-85.
7. Yanaka K, Nagase S, Asakawa H, Matsumaru Y, Koyama A, Nose T. Management of unruptured cerebral aneurysms in patients with polycystic kidney disease. *Surg Neurol* 2004;62:538-45.
8. Butler WE, Barker FG II, Crowell RM. Patients with polycystic kidney disease would benefit from routine magnetic resonance angiographic screening for intracerebral aneurysms: a decision analysis. *Neurosurgery* 1996;38:506-15.
9. The Magnetic Resonance Angiography in Relatives of Patients with Subarachnoid Hemorrhage Study Group. Risks and benefits of screening for intracranial aneurysms in first-degree relatives of patients with sporadic subarachnoid hemorrhage. *N Engl J Med* 1999;341:1344-50.
10. Stapf C, Mohr JP. Aneurysms and subarachnoid hemorrhage — epidemiology. In: Le Roux PD, Winn HR, Newell DW, eds. *Management of cerebral aneurysms*. Philadelphia: Saunders, 2004:183-7.
11. Greenberg MS. SAH and aneurysms. In: Greenberg MS, ed. *Handbook of neurosurgery*. 5th ed. New York: Thieme Medical, 2000:754-803.
12. Bederson JB, Awad IA, Wiebers DO, et al. Recommendations for the management of patients with unruptured intracranial aneurysms: a statement for healthcare professionals from the Stroke Council of the American Heart Association. *Stroke* 2000;31:2742-50.
13. Johnston SC, Selvin S, Gress DR. The burden, trends, and demographics of mortality from subarachnoid hemorrhage. *Neurology* 1998;50:1413-8.
14. Wiebers DO, Whisnant JP, Sundt TM Jr, O'Fallon WM. The significance of unruptured intracranial saccular aneurysms. *J Neurosurg* 1987;66:23-9.
15. Juvela S, Porras M, Heiskanen O. Natural history of unruptured intracranial aneurysms: a long-term follow-up study. *J Neurosurg* 1993;79:174-82.
16. Wiebers DO, Whisnant JP, O'Fallon WM. The natural history of unruptured intracranial aneurysms. *N Engl J Med* 1981;304:696-8.
17. Mount LA, Brisman R. Treatment of multiple aneurysms — symptomatic and asymptomatic. *Clin Neurosurg* 1974;21:166-70.
18. Winn HR, Almaani WS, Berga SL, Jane JA, Richardson AE. The long-term outcome in patients with multiple aneurysms: incidence of late hemorrhage and implications for treatment of incidental aneurysms. *J Neurosurg* 1983;59:642-51.
19. Raaymakers TW, Rinkel GJ, Limburg M, Algra A. Mortality and morbidity of surgery for unruptured intracranial aneurysms: a meta-analysis. *Stroke* 1998;29:1531-8.
20. King JT Jr, Berlin JA, Flamm ES. Morbidity and mortality from elective surgery for asymptomatic, unruptured, intracranial aneurysms: a meta-analysis. *J Neurosurg* 1994;81:837-42.
21. Solomon RA, Fink ME, Pile-Spellman J. Surgical management of unruptured

- intracranial aneurysms. *J Neurosurg* 1994; 80:440-6.
22. Kobayashi S, Orz Y, George B, et al. Treatment of unruptured cerebral aneurysms. *Surg Neurol* 1999;51:355-62.
23. Ausman JI. The New England Journal of Medicine report on unruptured intracranial aneurysms: a critique. *Surg Neurol* 1999;51:227-9.
24. Tsutsumi K, Ueki K, Morita A, Kirino T. Risk of rupture from incidental cerebral aneurysms. *J Neurosurg* 2000;93:550-3.
25. Juvela S, Porras M, Poussa K. Natural history of unruptured intracranial aneurysms: probability of and risk factors for aneurysm rupture. *J Neurosurg* 2000;93:379-87.
26. Le Roux PD, Winn HR. Management of the ruptured aneurysm. In: Le Roux PD, Winn HR, Newell DW, eds. Management of cerebral aneurysms. Philadelphia: Saunders, 2004:303-33.
27. Hunt WE, Hess RM. Surgical risk as related to time of intervention in the repair of intracranial aneurysms. *J Neurosurg* 1968;28:14-20.
28. Fisher CM, Kistler JP, Davis JM. Relation of cerebral vasospasm to subarachnoid hemorrhage visualized by computerized tomographic scanning. *Neurosurgery* 1980;6:1-9.
29. Edlow JA, Caplan LR. Avoiding pitfalls in the diagnosis of subarachnoid hemorrhage. *N Engl J Med* 2000;342:29-36.
30. Dammert S, Krings T, Moller-Hartmann W, et al. Detection of intracranial aneurysms with multislice CT: comparison with conventional angiography. *Neuroradiology* 2004;46:427-34.
31. Chappell ET, Moure FC, Good MC. Comparison of computed tomographic angiography with digital subtraction angiography in the diagnosis of cerebral aneurysms: a meta-analysis. *Neurosurgery* 2003;52:624-31.
32. White PM, Wardlaw JM, Easton V. Can noninvasive imaging accurately depict intracranial aneurysms? A systematic review. *Radiology* 2000;217:361-70.
33. White PM, Teasdale EM, Wardlaw JM, Easton V. Intracranial aneurysms: CT angiography and MR angiography for detection prospective blinded comparison in a large patient cohort. *Radiology* 2001;219:739-49.
34. Kouskouras C, Charitanti A, Giavroglou C, et al. Intracranial aneurysms: evaluation using CTA and MRA: correlation with DSA and intraoperative findings. *Neuroradiology* 2004;46:842-50.
35. Okahara M, Kiyosue H, Yamashita M, et al. Diagnostic accuracy of magnetic resonance angiography for cerebral aneurysms in correlation with 3D-digital subtraction angiographic images: a study of 133 aneurysms. *Stroke* 2002;33:1803-8.
36. Harrison MJ, Johnson BA, Gardner GM, Welling BG. Preliminary results on the management of unruptured intracranial aneurysms with magnetic resonance angiography and computed tomographic angiography. *Neurosurgery* 1997;40:947-55.
37. Kangasniemi M, Makela T, Koskinen S, Porras M, Poussa K, Hernesniemi J. Detection of intracranial aneurysms with two-dimensional and three-dimensional multislice helical computed tomographic angiography. *Neurosurgery* 2004;54:336-40.
38. Tipper G, U-King-Im JM, Price SJ, et al. Detection and evaluation of intracranial aneurysms with 16-row multislice CT angiography. *Clin Radiol* 2005;60:565-72.
39. Anxionnat R, Bracard S, Ducrocq X, et al. Intracranial aneurysms: clinical value of 3D digital subtraction angiography in the therapeutic decision and endovascular treatment. *Radiology* 2001;218:799-808.
40. Tanoue S, Kiyosue H, Kenai H, Nakamura T, Yamashita M, Mori H. Three-dimensional reconstructed images after rotational angiography in the evaluation of intracranial aneurysms: surgical correlation. *Neurosurgery* 2000;47:866-71.
41. Hoh BL, Cheung AC, Rabinov JD, Pryor JC, Carter BS, Ogilvy CS. Results of a prospective protocol of computed tomographic angiography in place of catheter angiography as the only diagnostic and pretreatment planning study for cerebral aneurysms by a combined neurovascular team. *Neurosurgery* 2004;54:1329-40.
42. Heiserman JE, Dean BL, Hodak JA, et al. Neurologic complications of cerebral angiography. *AJNR Am J Neuroradiol* 1994;15:1401-7.
43. Dion JE, Gates PC, Fox AJ, Barnett HJ, Blom RJ. Clinical events following neuroangiography: a prospective study. *Stroke* 1987;18:997-1004.
44. Connors JJ III, Sacks D, Furlan AJ, et al. Training, competency, and credentialing standards for diagnostic cervicocerebral angiography, carotid stenting, and cerebrovascular intervention: a joint statement from the American Academy of Neurology, the American Association of Neurological Surgeons, the American Society of Interventional and Therapeutic Neuroradiology, the American Society of Neuroradiology, the Congress of Neurological Surgeons, the AANS/CNS Cerebrovascular Section, and the Society of Interventional Radiology. *Neurology* 2005;64:190-8.
45. Morris P. Practical neuroangiography. Baltimore: Williams & Wilkins, 1997.
46. van Gijn J, Rinkel GJ. Subarachnoid haemorrhage: diagnosis, causes and management. *Brain* 2001;124:249-78.
47. Barker FG II, Ogilvy CS. Efficacy of prophylactic nimodipine for delayed ischemic deficit after subarachnoid hemorrhage: a metaanalysis. *J Neurosurg* 1996;84:405-14.
48. Elliott JP, Newell DW, Lam DJ, et al. Comparison of balloon angioplasty and papaverine infusion for the treatment of vasospasm following aneurysmal subarachnoid hemorrhage. *J Neurosurg* 1998;88:277-84.
49. Rosenwasser RH, Armonda RA, Thomas JE, Benitez RP, Gannon PM, Harrop J. Therapeutic modalities for the management of cerebral vasospasm: timing of endovascular options. *Neurosurgery* 1999;44:975-9.
50. Rabinstein AA, Friedman JA, Nichols DA, et al. Predictors of outcome after endovascular treatment of cerebral vasospasm. *AJNR Am J Neuroradiol* 2004;25:1778-82.
51. Polin RS, Coenen VA, Hansen CA, et al. Efficacy of transluminal angioplasty for the management of symptomatic cerebral vasospasm following aneurysmal subarachnoid hemorrhage. *J Neurosurg* 2000;92:284-90.
52. Eskridge JM, McAuliffe W, Song JK, et al. Balloon angioplasty for the treatment of vasospasm: results of first 50 cases. *Neurosurgery* 1998;42:510-6.
53. Zaroff JG, Rordorf GA, Newell JB, Ogilvy CS, Levinson JR. Cardiac outcome in patients with subarachnoid hemorrhage and electrocardiographic abnormalities. *Neurosurgery* 1999;44:34-9.
54. Jain R, Deveikis J, Thompson BG. Management of patients with stunned myocardium associated with subarachnoid hemorrhage. *AJNR Am J Neuroradiol* 2004;25:126-9.
55. Deibert E, Barzilai B, Braverman AC, et al. Clinical significance of elevated troponin I levels in patients with nontraumatic subarachnoid hemorrhage. *J Neurosurg* 2003;98:741-6.
56. Bulsara KR, McGirt MJ, Liao L, et al. Use of the peak troponin value to differentiate myocardial infarction from reversible neurogenic left ventricular dysfunction associated with aneurysmal subarachnoid hemorrhage. *J Neurosurg* 2003;98:524-8.
57. Tung P, Kopelnik A, Banki N, et al. Predictors of neurocardiogenic injury after subarachnoid hemorrhage. *Stroke* 2004;35:548-51.
58. Khush K, Kopelnik A, Tung P, et al. Age and aneurysm position predict patterns of left ventricular dysfunction after subarachnoid hemorrhage. *J Am Soc Echocardiogr* 2005;18:168-74.
59. Zaroff JG, Rordorf GA, Ogilvy CS, Picard MH. Regional patterns of left ventricular systolic dysfunction after subarachnoid hemorrhage: evidence for neurally mediated cardiac injury. *J Am Soc Echocardiogr* 2000;13:774-9.
60. Friedman DP, Maitino AJ. Endovascular interventional neuroradiologic procedures: who is performing them, how often, and where? A survey of academic and non-academic radiology practices. *AJNR Am J Neuroradiol* 2003;24:1772-7.
61. Qureshi AI, Suri MF, Khan J, et al. Endovascular treatment of intracranial aneurysms by using Guglielmi detachable

- coils in awake patients: safety and feasibility. *J Neurosurg* 2001;94:880-5.
62. Liu AY, Lopez JR, Do HM, Steinberg GK, Cockcroft K, Marks MP. Neurophysiological monitoring in the endovascular therapy of aneurysms. *AJNR Am J Neuroradiol* 2003;24:1520-7.
63. Thornton J, Bashir Q, Aletich VA, Debrun GM, Ausman JI, Charbel FT. What percentage of surgically clipped intracranial aneurysms have residual necks? *Neurosurgery* 2000;46:1294-8.
64. David CA, Vishteh AG, Spetzler RF, Lemole M, Lawton MT, Partovi S. Late angiographic follow-up review of surgically treated aneurysms. *J Neurosurg* 1999;91:396-401.
65. Tummala RP, Baskaya MK, Heros RC. Contemporary management of incidental intracranial aneurysms. *Neurosurg Focus* 2005;18(1):e9.
66. Johnston SC, Higashida RT, Barrow DL, et al. Recommendations for the endovascular treatment of intracranial aneurysms: a statement for healthcare professionals from the Committee on Cerebrovascular Imaging of the American Heart Association Council on Cardiovascular Radiology. *Stroke* 2002;33:2536-44.
67. Friedman JA, Nichols DA, Meyer FB, et al. Guglielmi detachable coil treatment of ruptured saccular cerebral aneurysms: retrospective review of a 10-year single-center experience. *AJNR Am J Neuroradiol* 2003;24:526-33.
68. Murayama Y, Nien YL, Duckwiler G, et al. Guglielmi detachable coil embolization of cerebral aneurysms: 11 years' experience. *J Neurosurg* 2003;98:959-66.
69. Tummala RP, Chu RM, Madison MT, Myers M, Tubman D, Nussbaum ES. Outcomes after aneurysm rupture during endovascular coil embolization. *Neurosurgery* 2001;49:1059-66.
70. Cloft HJ, Kallmes DF. Cerebral aneurysm perforations complicating therapy with Guglielmi detachable coils: a meta-analysis. *AJNR Am J Neuroradiol* 2002;23:1706-9.
71. Brisman JL, Niimi Y, Song JK, Berenstein A. Aneurysmal rupture during coiling: low incidence and good outcomes at a single large volume center. *Neurosurgery* 2005;57:1103-9.
72. Henkes H, Fischer S, Weber W, et al. Endovascular coil occlusion of 1811 intracranial aneurysms: early angiographic and clinical results. *Neurosurgery* 2004;54:268-80.
73. Brillstra EH, Rinkel GJ, van der Graaf Y, van Rooij WJ, Algra A. Treatment of intracranial aneurysms by embolization with coils: a systematic review. *Stroke* 1999;30:470-6.
74. Shanno GB, Armonda RA, Benitez RP, Rosenwasser RH. Assessment of acutely unsuccessful attempts at detachable coiling in intracranial aneurysms. *Neurosurgery* 2001;48:1066-72.
75. Moret J, Cognard C, Weill A, Castaings L, Rey A. Reconstruction technic in the treatment of wide-neck intracranial aneurysms: long-term angiographic and clinical results: apropos of 56 cases. *J Neuro-radiol* 1997;24:30-44. (In French.)
76. Lylyk P, Ferrario A, Pasbon B, Miranda C, Dorozuk G. Buenos Aires experience with the Neuroform self-expanding stent for the treatment of intracranial aneurysms. *J Neurosurg* 2005;102:235-41.
77. Brisman JL, Song JK, Niimi Y, Berenstein A. Treatment options for wide-necked intracranial aneurysms using a self-expandable hydrophilic coil and a self-expandable stent combination. *AJNR Am J Neuroradiol* 2005;26:1237-40.
78. Thornton J, Debrun GM, Aletich VA, Bashir Q, Charbel FT, Ausman J. Follow-up angiography of intracranial aneurysms treated with endovascular placement of Guglielmi detachable coils. *Neurosurgery* 2002;50:239-49.
79. Raymond J, Guilbert F, Weill A, et al. Long-term angiographic recurrences after selective endovascular treatment of aneurysms with detachable coils. *Stroke* 2003;34:1398-403.
80. Slob MJ, Sluzewski M, van Rooij WJ, Roks G, Rinkel GJ. Additional coiling of previously coiled cerebral aneurysms: clinical and angiographic results. *AJNR Am J Neuroradiol* 2004;25:1373-6.
81. Murayama Y, Tatehima S, Gonzalez NR, Vinuela F. Matrix and bioabsorbable polymeric coils accelerate healing of intracranial aneurysms: long-term experimental study. *Stroke* 2003;34:2031-7.
82. Cloft HJ, Kallmes DF. Aneurysm packing with HydroCoil Embolic System versus platinum coils: initial clinical experience. *AJNR Am J Neuroradiol* 2004;25:60-2.
83. Yoshino Y, Niimi Y, Song JK, Silane M, Berenstein A. Endovascular treatment of intracranial aneurysms: comparative evaluation in a terminal bifurcation aneurysm model in dogs. *J Neurosurg* 2004;101:996-1003.
84. Johnston SC, Wilson CB, Halbach VV, et al. Endovascular and surgical treatment of unruptured cerebral aneurysms: comparison of risks. *Ann Neurol* 2000;48:11-9.
85. Johnston SC, Zhao S, Dudley RA, Berman MF, Gress DR. Treatment of unruptured cerebral aneurysms in California. *Stroke* 2001;32:597-605.
86. Johnston SC, Dudley RA, Gress DR, Ono L. Surgical and endovascular treatment of unruptured cerebral aneurysms at university hospitals. *Neurology* 1999;52:1799-805.
87. Molyneux A, Kerr R, Stratton I, et al. International Subarachnoid Aneurysm Trial (ISAT) of neurosurgical clipping versus endovascular coiling in 2143 patients with ruptured intracranial aneurysms: a randomised trial. *Lancet* 2002;360:1267-74.
88. Molyneux AJ, Kerr RS, Yu LM, et al. International Subarachnoid Aneurysm Trial (ISAT) of neurosurgical clipping versus endovascular coiling in 2143 patients with ruptured intracranial aneurysms: a randomised comparison of effects on survival, dependency, seizures, rebleeding, subgroups, and aneurysm occlusion. *Lancet* 2005;366:809-17.
89. Lindsay KW. The impact of the International Subarachnoid Aneurysm Treatment Trial (ISAT) on neurosurgical practice. *Acta Neurochir (Wien)* 2003;145:97-9.
90. Maurice-Williams RS. Aneurysm surgery after the International Subarachnoid Aneurysm Trial (ISAT). *J Neurol Neurosurg Psychiatry* 2004;75:807-8.
91. Derdeyn CP, Barr JD, Berenstein A, et al. The International Subarachnoid Aneurysm Trial (ISAT): a position statement from the Executive Committee of the American Society of Interventional and Therapeutic Neuroradiology and the American Society of Neuroradiology. *AJNR Am J Neuroradiol* 2003;24:1404-8.
92. Harbaugh RE, Heros RC, Hadley MN. Position statement on the International Subarachnoid Aneurysm Trial (ISAT). (Accessed August 4, 2006, at <http://www.aans.org/Library/Article.aspx?ArticleId=9703>.)
93. Barker FG II, Amin-Hanjani S, Butler WE, Ogilvy CS, Carter BS. In-hospital mortality and morbidity after surgical treatment of unruptured intracranial aneurysms in the United States, 1996-2000: the effect of hospital and surgeon volume. *Neurosurgery* 2003;52:995-1007.
94. Berman MF, Solomon RA, Mayer SA, Johnston SC, Yung PP. Impact of hospital-related factors on outcome after treatment of cerebral aneurysms. *Stroke* 2003;34:2200-7.
95. Bardach NS, Zhao S, Gress DR, Lawton MT, Johnston SC. Association between subarachnoid hemorrhage outcomes and number of cases treated at California hospitals. *Stroke* 2002;33:1851-6.
96. Johnston SC. Effect of endovascular services and hospital volume on cerebral aneurysm treatment outcomes. *Stroke* 2000;31:111-7.
97. Solomon RA, Mayer SA, Tarmey JJ. Relationship between the volume of craniotomies for cerebral aneurysm performed at New York state hospitals and in-hospital mortality. *Stroke* 1996;27:13-7.

Copyright © 2006 Massachusetts Medical Society.